

## THE HISTORICAL CASE OF GIULIO CLOVIO (JULIJE KLOVIĆ, 1498-1578): ANATOMO-CLINICAL ANALYSIS AND DIFFERENTIAL DIAGNOSIS

VERONICA PAPA<sup>1,2\*</sup>, ELENA VAROTTO<sup>2,3,4</sup>, MARIO NOVAK<sup>5</sup>, ANTONIO ASCIONE<sup>6</sup>, FRANCESCO MARIA GALASSI<sup>2,3</sup>

<sup>1</sup>University of Naples "Parthenope", Naples, Italy - <sup>2</sup>Forensic Anthropology, Paleopathology and Bioarchaeology (FAPAB) Research Center, Avola, Italy - <sup>3</sup>Flinders University, Adelaide, SA, Australia - <sup>4</sup>University of Catania, Catania, Sicily, Italy - <sup>5</sup>Centre for Applied Bioanthropology, Institute for Anthropological Research, Zagreb, Croatia - <sup>6</sup>University of Bari "Aldo Moro", Bari, Italy

### ABSTRACT

**Introduction:** Blepharitis is a common chronic inflammatory process of the eyelid margin that may be associated with several systemic conditions. Symptoms associated with blepharitis include burning sensation, irritation, tearing, photophobia, blurred vision, and red eyes. Moreover, red eye and conjunctivitis-blepharitis are among the most common ocular diseases in elderly patients and may be described in association with ocular rosacea.

**Case presentation:** In the paper that follows, the authors detail and discuss the case of Giulio Clovio (Julije Klović, 1498-1578), the famous 15th century Croatian miniaturist. His portrait, clearly showing this common ocular condition, was painted by El Greco in 1570/1571 and is currently exhibited in the Capodimonte Museum in Naples, Italy (inv #Q191). The differential diagnosis of staphylococcal blepharitis secondary to rosacea has been suggested on the basis of the clinical history derived from the reassessment of historical sources as well as the accurate examination of the painting.

**Conclusion:** The possibility of ocular rosacea should be considered in evaluating an elderly patient with persistent red eye and relapsing conjunctivitis-blepharitis.

**Keywords:** blepharitis, ocular rosacea, palaeopathology, differential diagnosis.

DOI: 10.19193/0393-6384\_2021\_6\_491

Received June 15, 2021; Accepted August 20, 2021

### Introduction

Blepharitis is currently recognised as one of the most widespread ocular conditions. It affects people of all ages, ethnicities, and gender but is more common in individuals older than the age of 50<sup>(1,2)</sup>. Commonly defined as an inflammation of the eyelids, it is characterised by a broad range of signs and symptoms including irritation, hyperaemia, foreign-body sensation, and crusting of the eyelids eventually leading to visual symptoms such as light sensitivity and blurred vision. Moreover, blepharitis might be associated with various dermatological conditions, including seborrhoeic dermatitis,

rosacea, and eczema<sup>(3)</sup>. Less frequently, it can result in permanent changes to the eyelid morphology and visual deficits due to keratopathy and corneal ulceration<sup>(1)</sup>.

The pathogenesis of this disease is far from being fully elucidated. Nevertheless, it is likely to be a multifactorial condition that might have a bacterial, viral, or parasitic aetiology<sup>(4)</sup>.

Although blepharitis is not a sight-threatening condition, if untreated it can lead to keratopathy, corneal neovascularisation and ulceration, and permanent alterations in eyelid morphology. Since its first scientific descriptions in the 19th century by Dalrymple<sup>(5)</sup> and Lydston - the latter reporting on a

clinical entity named conjunctivitis meibomiae in a patient with accumulated sebaceous-like material in the meibomian glands (named after the German physician Heinrich Meibom, 1638-1700 and responsible for the production of meibum, a substance which prevents the eyes' tear film from evaporating) - the terminology for blepharitis has evolved through history along with the understandings of its pathophysiology and treatment<sup>(6)</sup>. Moreover, it can be classified according to multiple structural classifications, including anatomical location, duration, and aetiology.

It can be acute or chronic, anterior or posterior as well as primary or secondary where primary blepharitis typically refers to rosacea, seborrhoea, and hypersensitivity caused by Staphylococcal toxins. Secondary blepharitis refers to infectious processes, bacterial or viral, or infestation by Phthiriasis palpebrarum or Demodex<sup>(7,8)</sup>.

Although considered one of the most common chronic inflammatory diseases of the skin, rosacea may involve the eyes in 58-72% of patients causing eyelid and ocular surface inflammation<sup>(9)</sup>.

Moreover, rosacea is closely associated with the dysfunction and inflammation of the Meibomian glands. Dysfunction of these ocular glands might causes an abnormal lipid composition of the tear film, which leads to thickened secretions, and consequently dryness of the eye surface<sup>(10)</sup>.

Here, the authors discuss a differential diagnosis in the famous historical personage Giulio Clovio (Croatian: Julije Klović, 1498-1578), a renowned painter of ornamental decoration and famous Renaissance miniaturist, who possibly suffered from conjunctivitis-blepharitis in association with ocular rosacea, by jointly assessing historical and artistic sources, and by contextualising the historical background in order to prove their statement. This approach was implemented since no access to Clovio's mortal remains is a viable possibility at present (Clovio is buried in the San Pietro in Vincoli church in Rome) and ocular conditions can only be effectively investigated in mummified or embalmed human remains.

## Case Presentation

The presented hypothesis was suggested by the Portrait of Giulio Clovio by El Greco (pseudonym for Δομήνικος Θεοτοκόπουλος, 1541-1614) currently exhibited in the Capodimonte Museum in Naples, Italy (inv #Q191), part of the Farnese

Collection. It dates to 1570-71 and was painted by El Greco probably in gratitude for his friend Giulio Clovio's request of protection for El Greco to his patron Alessandro Farnese (1545-1592). At the time of the portrait, Giulio Clovio was 72 years old<sup>(11)</sup>.

## Differential Diagnosis

### Historical sources

In an exchange of letters with the Duchess of Parma Margaret of Austria, at the beginning of 1561, complained about the delay in the delivery of the painting of *Judith* that she committed to Clovio: «[...] *sollecitar don Giulio, acciò, quanto prima gli sarà possibile dia fine al quadretto*[...]» («urge don Giulio to finish the painting as soon as possible [...]»)<sup>(12)</sup>.

The Croatian painter replied on 11th September 1561 and apologised for his delay due to his health problems:

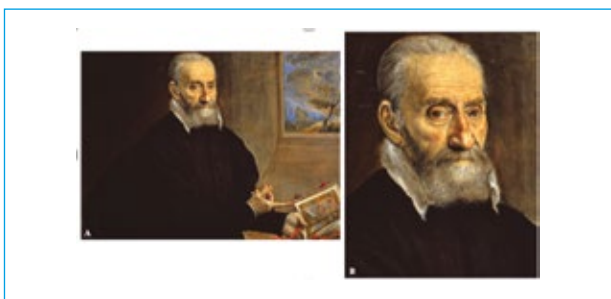
«*Mando a V. Altezza il quadro della Giuditta, finito per una volta, quando è piaciuto a Dio. Dico così, perchè [...] tanti mali, e da tanti sinistri così della vita, come della fortuna, che se non fosse stato l'ardore e la divozione con che ci ho lavorato, credo che non ne sarei mai venuto a capo. [...]*» («I send Your Highness the painting of Judith, finished at last, when it pleased God. I say this because [...] so many evils, and from so many accidents, both of life and of fortune, that if it had not been for the ardour and devotion with which I worked on it, I believe I would never have brought it to an end.»)<sup>(13)</sup>.

The letter was written by Annibale Caro (1507-1566), on behalf of Giulio Clovio testifying the miniaturist's difficulty writing and painting. Moreover, a third letter was recently discovered by Ferber Bogdan in 2017<sup>(14)</sup>. In this letter, recently re-dated 1754, the sender is positively identified by the signature, while the handwriting is most likely not Clovio's, except for the signature at the bottom of the letter, which is not unusual, since many of his known letters were written by a notary or, on a few earlier occasions, by his friend Annibale Caro. Furthermore, in 2001 Dorn clearly mentioned the letter that Clovio sent to Cardinal Farnese in 1558 where he speaks in detail about his eye problem and the subsequent surgery that eased the problems for a while. Based on this evidence, Dorn presumes that the main basis for Clovio's eye ailment was blepharitis<sup>(15)</sup>. Generally, the most frequent type of blepharon-conjunctivitis is mixed chronic seborrhoeic/staphylococcal blepharitis that may

lead to recidivism of hordeolum and chalazion. In more serious cases the infection of the Meibomian glands eventually evolved in encapsulated chalazion and acute purulent infection with the occurrence of partial or developed eyelid abscess<sup>(2,9)</sup>. According to Dorn's description of the course of the disease as well as of the surgical procedure, it is likely that Clovio might have suffered from such an infection.

### Investigations

Blepharitis was suspected on the basis of the accurate visual examination of the Portrait of Giulio Clovio by El Greco currently exhibited at the Capodimonte Museum in Naples, Italy (inv #Q191; Figure 1) as well as Clovio's self-portrait (ca 1573) housed in the Uffizi Gallery in Florence (inv# 4213 – 1890; Figure 2A), and the painting *Christ Driving the Money Changers from the Temple* (ca. 1570-75) by El Greco currently located at the Institute of Arts in Minneapolis, USA (inv #522; Figure 2B). The most frequent cause of blepharitis is seborrheic disposition and staphylococcal infection, but refraction errors (especially non-corrected hypermetropia), anisometropia, astigmatism, and other systemic conditions may be associated. In his self-portrait (Figure 2A), Clovio is represented as a 70-year-old man with roan greyish eyes, reddish eyelid edges suggesting seborrhoea, and exudative diatheses.



**Figure 1:** A-The portrait of Giulio Clovio (El Greco, 1570-71) Capodimonte Museum, Naples, Italy (inv #Q191). B- magnification of the miniaturist's face. Source: Archives of the Capodimonte Museum, Naples, Italy.

Moreover, on the large canvas exhibited at the Institute of Arts in Minneapolis, USA (Figure 2B), El Greco showed Clovio beside Titian, Michelangelo and Raphael in the lower right corner. The miniaturist was represented with sunken eyes due to senile atrophy of the orbital tissue as well as subcutaneous lobule of the orbital soft tissue, superiorly in the nasal eye corners. Clovio also showed redness of the middle part of the face, cheeks and a prominent

nose, clinical signs suggestive of rosacea. Also, there are obvious red and thickened eyelid edges, especially of the lower eyelid, and they also look uneven. These ocular signs are even more evident on the famous Clovio portrait painted by El Greco in 1570/71 (Figure 1). Beside the already described redness of the nose and the face, red, thickened and uneven eyelid edges are clearly visible. Furthermore, on the lower eyelids the edge is twisted out. The upper eyelid of the left eye is completely uneven and slightly showing old scarring changes, maybe due to the alteration of the eyelid morphology caused by recurrent blepharitis.



**Figure 2:** A- Giulio Clovio self-portrait (1573) Uffizi Gallery, Florence, Italy (inv# 4213 – 1890). Source: Wikimedia: [https://www.wikigallery.org/wiki/painting\\_170613/Giorgio-Giulio-Clovio/Self-Portrait](https://www.wikigallery.org/wiki/painting_170613/Giorgio-Giulio-Clovio/Self-Portrait). Copyright expired; B- Christ Driving the Money Changers from the Temple (El Greco, ca. 1570-75) Clovio is represented in the lower right corner (white arrow), Institute of Arts in Minneapolis, USA (inv #522). Source: Wikimedia:[https://en.wikipedia.org/wiki/Christ\\_Driving\\_the\\_Money\\_Changers\\_from\\_the\\_Temple\\_\(El\\_Greco,\\_Minneapolis\)#/media/File:El\\_Greco\\_\(Domenikos\\_Theotokopoulos\)\\_Christ\\_Driving\\_the\\_Money\\_Changers\\_from\\_the\\_Temple\\_-\\_Google\\_Art\\_Project.jpg](https://en.wikipedia.org/wiki/Christ_Driving_the_Money_Changers_from_the_Temple_(El_Greco,_Minneapolis)#/media/File:El_Greco_(Domenikos_Theotokopoulos)_Christ_Driving_the_Money_Changers_from_the_Temple_-_Google_Art_Project.jpg)

Finally, on Clovio's portraits painted by El Greco but also on his self-portraits (Figure 1 and 2A) the miniaturist, now old, is shown not wearing glasses. Nevertheless, it is likely that Clovio used to wear glasses, which were included in his will and inventory of his earthly possessions drawn up by the notary Livius Prata in 1577/78 where «*una casseta con doi pari d'ochalli d'argento*» («a small box with a pair of silver glasses») are mentioned – spectacles having been available in Italy since as early as the 13<sup>th</sup> century. Therefore, Clovio most likely suffered from old-age related hyperopia (farsightedness), and he used to wear reading glasses. In the years after his eye disorder and the surgery Clovio started to complain about fatigue, his advances years, weakness, headache, and eye problems. This symptomatology should also make any investigator

consider Horton's arteritis as a potential alternative diagnosis, yet the anatomy of the temporal region does not show a patent turgidity of the temporal artery, while the observed vessel on the right temple seems to be the temporal vein and the whole region lacks an inflammatory presentation. Clovio had major eye problems during the last stages of his life, and these were probably due to chronic blepharitis or sty, which can be recurring. It is also possible that he got the first symptoms of senile grey, senile cataract.

## Discussion and conclusion

Red eye, ocular dryness, burning and foreign body sensation and relapsing conjunctivitis-blepharitis are frequent clinical condition in the elderly population. Moreover, ocular rosacea is often underdiagnosed and untreated. Based on observation of clinical features, the diagnosis of ocular rosacea may be challenging whether or not roseatic and facial dermatosis are evident symptoms.

Therefore, the possibility of ocular rosacea should be considered in evaluating an elderly patient with persistent red eye and relapsing conjunctivitis-blepharitis. Finally, this case once again underlines the importance of a multidisciplinary assessment of historical and artistic sources and their helpfulness in reconstructing the antiquity of disease in the absence of or together with ancient human remains, whenever preserved or available for study.

## References

- 1) Putnam CM. Diagnosis and management of blepharitis: an optometrist's perspective. *Clin Optom (Auckl)* 2016; 8: 71-78.
- 2) Nelson JD, Shimazaki J, Benitez-del Castillo JM, Craig JP, McCulley JP, Den S, Foulks GN. The international workshop on meibomian gland dysfunction: report of the definition and classification subcommittee. *Invest Ophthalmol Vis Sci* 2001; 4: 1930-1937.
- 3) Lemp MA, Nichols KK. Blepharitis in the United States 2009: a survey-based perspective on prevalence and treatment. *Ocul Surf* 2009; 7(Suppl 2): 1-14.
- 4) Bernardes TF, Bonfioli AA. Blepharitis. *Semin Ophthalmol* 2010; 3: 79-83.
- 5) Ayliffe W. Blepharitis and Meibomian Gland Dysfunction. In: Smolin G, Foster CS, Azar DT, Dohlman CH. Smolin and Thoft's The Cornea: Scientific Foundations and Clinical Practice. Lippincott Williams & Wilkins, 2005; 647.
- 6) Lydston JA. Conjunctivitis Meibomianæ. *JAMA* 1894; 23(6): 241-242
- 7) Khoo P, Ooi KG, Watson S. Effectiveness of pharmaceutical interventions for meibomian gland dysfunction: An evidence-based review of clinical trials. *Clin Exp Ophthalmol* 2019; 5: 658-668.
- 8) Soh Qin R, Tong Hak Tien L. Healthcare delivery in meibomian gland dysfunction and blepharitis. *Ocul Surf* 2019; 2: 176-178.
- 9) De Marchi SU, Cecchin E, De Marchi S. Ocular rosacea: an underdiagnosed cause of relapsing conjunctivitis-blepharitis in the elderly. *BMJ Case Rep.* 2014 Sep 19; 2014: bcr2014205146.
- 10) Lazaridou E, Fotiadou C, Ziakas NG, Giannopoulou C, Apalla Z, Ioannides D. Clinical and laboratory study of ocular rosacea in northern Greece. *J Eur Acad Dermatol Venereol* 2011; 25: 1428-31.
- 11) Bertolotti A. Don Giulio Clovio. Principe dei miniatori. *Notizie e documenti inediti. Atti e Memorie delle R. Deputazioni di storia patria dell'Emilia* 1882; VII: 259-79.
- 12) Archivio di Stato di Napoli, Archivio Farnesiano. Naples; 1883.
- 13) National Library, n°1707. Paris.
- 14) Ferber Bogdan J. Patrona and Servitor – New Insights into the Patron/Artist Relationship between Duchess Margaret of Parma and Giulio Clovio. *Radovi Instituta za povijest umjetnosti* 2017; 41: 109-118.
- 15) Dorn V. O očnoj bolesti i drugim zdravstvenim tegobama Jurja Julija Klovića, in Klovićev zbornik: minijatura, crtež, grafika 1450.-1700.: zbornik radova sa znanstvenoga skupa povodom petstote obljetnice rođenja Jurja Julija Klovića, Zagreb, 22.-24. listopada 1998, edited by M. Pelc, Zagreb: Hrvatska akademija znanosti i umjetnosti : Institut za povijest umjetnosti, 2001; 85-97.

*Acknowledgments: All authors declare that there have been no involvements that might raise the question of bias in the work reported or in the conclusions, implications, or opinions stated. The authors wish to thank the Capodimonte Museum of Naples for the kind permission to reproduce images of the analysed artwork. This research did not receive any specific grant from funding agencies in public, commercial or not-for-profit sectors.*

*Corresponding Author:*  
 DR VERONICA PAPA, Ph.D,  
 University of Naples "Parthenope"  
 Via Medina 40  
 80133 Naples  
 Email: veronica.papa@uniparthenope.it  
 (Italy)