

## FLEXIBLE FIBEROPTIC LARYNGOSCOPE GUIDED INTUBATION IN DIFFICULT ORAL INTUBATION: AN AIRWAY MANAGEMENT CHALLENGE IN DENTAL ABSCESS INDUCED TRISMUS

CALOGERO GRILLO<sup>1</sup>, FRANCESCO SGALAMBRO<sup>2</sup>, CATERINA GRILLO<sup>1</sup>, CLAUDIO ANDALORO<sup>1</sup>, GIUSEPPE FUGALE<sup>1</sup>, ALESSIO FALLICA<sup>1</sup>, SALVATORE FERLITO<sup>1</sup>

<sup>1</sup>Department of Medical Surgical Specialties, ENT Clinic, University Hospital "Vittorio Emanuele-Policlinico" Catania -

<sup>2</sup>Department of Anaesthesia and Intensive Care Oncology Institute of the Mediterranean Viagrande, Catania, Italy

### ABSTRACT

**Introduction:** Odontogenic abscesses with the involvement of facial or cervical spaces can be life-threatening and often have to be drained under general anaesthesia. Trismus and swelling can make intubation with a Macintosh laryngoscope difficult or even impossible. However, several indirect laryngoscopes and procedures are available to facilitate tracheal intubation when conventional direct laryngoscopy has failed but the success and safety of these techniques in patients with a complicated airway management have not yet been established.

**Methods:** We retrospectively compared two different approaches for tracheal intubation in 100 patients with severe cervicofacial dental abscess induced trismus: Nasotracheal intubation with flexible fiberoptic laryngoscope and orotracheal intubation with the aid of a conventional Macintosh laryngoscope. All patients were scheduled for surgical incision and drainage of the abscess under general anaesthesia. Depending on pre-operative airway evaluation, patients were allocated to expected easy or difficult intubation groups, on the basis of mouth opening, modified Mallampati score, history of difficult intubation, obvious swelling or reduced oropharyngeal space. Success rate, visualization of the glottis and intubation duration were evaluated.

**Results:** All the expected easy intubations were successfully performed with the respective technique. In the expected difficult intubation group, the success rate was higher (25/27 vs 6/23;  $p < 0.01$ ), the view at the glottis was better ( $p < 0.01$ ) and intubation duration was shorter ( $p < 0.01$ ) with the flexible fiberoptic laryngoscope compared with the Macintosh, respectively.

**Conclusion:** In patients with odontogenic abscesses and difficult tracheal intubations, the use of a flexible fiberoptic laryngoscope is more effective than the Macintosh laryngoscope.

**Key words:** Difficult intubation, dental abscess, trismus, flexible fiberoptic laryngoscopy.

Received November 30, 2014; Accepted May 02, 2015

### Introduction

Odontogenic abscesses are the most frequent cause of inflammatory conditions in the cervicofacial region, although the widespread availability of antibiotics has reduced their incidence drastically<sup>(1-2)</sup>.

They should be suspected in patients presenting with an acute cervicofacial swelling or trismus<sup>(3)</sup>. Trismus is the inability to normally open the mouth. Inflammation of soft tissue around impacted third molar tooth is the most common cause of trismus. Other causes include tetanus, inflammation of muscles of mastication, peritonsillar

abscess, temporomandibular joint disorders, as a temporary side effect of many stimulants of the sympathetic nervous system and some recreational drugs<sup>(4)</sup>. The degree of trismus should be evaluated using a ruler to measure the vertical distance between the upper and lower central incisor teeth (inter-incisor distance). An inter-incisor opening of less than 30 mm correlates with difficulties in endotracheal intubation<sup>(5)</sup>. Odontogenic abscesses are potentially life-threatening diseases, where delayed diagnosis or inadequate treatment can easily lead to further serious complications and even fatal end by developing sepsis, or by the direct

spread to vital organs or areas, typically into the mediastinal space<sup>(6,7)</sup> such as Ludwig's angina and necrotizing mediastinitis (8). However, in the last decades, there is a significant increase in survival rates, but mortality still can reach 11%<sup>(9)</sup>. So a careful assessment and management with an early incision and drainage, mostly under general anaesthesia, of all spaces affected by the abscess is required to prevent or minimize the development of these complications<sup>(10)</sup>.

This generally involves an otolaryngologist, a dentist and an anesthetist, this latter necessary for an adequate airway management plan particularly for those cases where tracheal intubation can be complicated by the presence of trismus, intraoral and/or pharyngeal swelling and can be difficult or even impossible when performed with a conventional direct laryngoscopy<sup>(11)</sup>. Several indirect laryngoscopes and procedures are available to facilitate tracheal intubation where conventional direct laryngoscopy failed, but the success and safety of these techniques in patients with cervicofacial abscesses and complicated airway management have not yet been established<sup>(12)</sup>.

This study summarizes our experience with two different approaches for tracheal intubation of patients with severe odontogenic abscesses that had spread into the facial or cervical spaces and had caused an interincisor distance of < 30 mm: Nasotracheal intubation with flexible fiberoptic laryngoscope and orotracheal intubation with Macintosh laryngoscope.

## Material and methods

At the ENT Clinic of the Medical-Surgical Specialties Department of the University of Catania, a retrospective study, regarding the period between January 2013 and April 2014 has been carried out.

This work has included 100 patients (52 men and 48 women, mean age 39 years, range 26-56) scheduled for surgical incision and drainage of an odontogenic abscess under general anaesthesia. We have enlisted in the study only patients with an abscess of the deep facial or cervical spaces, patients with a superficial abscess that could be drained intra-orally without drainage of the adjacent spaces were excluded.

Patients were divided into two groups of 50 patients each, depending on airway evaluation findings at the pre-operative visit. Each of the two

groups has been further divided into two subgroups: Macintosh and flexible fiberoptic laryngoscope subgroups according to the technique used for the intubation. All cases where intubation with the conventional Macintosh laryngoscope or flexible fiberoptic laryngoscope failed, despite a maximum of three attempts, they were considered as failed intubations<sup>(13)</sup>.

Patients with difficult intubation predictors, such as inter-incisor distance of 30 mm or less, a modified Mallampati score of > 3, documented history of difficult intubation, obvious swelling and/or reduced oropharyngeal space, were included in the expected difficult intubation group. The other patients were included in the expected easy intubation group. Before induction of anaesthesia, the inter-incisor distance during maximal active mouth opening was measured and the modified Mallampati score was assessed with the patient in the sitting position. For the assessment of the Mallampati score, the patients were asked to open their mouths as widely as possible and to protrude their tongues when possible<sup>(14)</sup>. At tracheal intubation, the visualization of the laryngeal inlet was assessed according to the classification of Cormack and Lehane: I, vocal cords visible; II, less than half of the glottis or only the posterior commissure is visible; III, only the epiglottis is visible; IV, none of the foregoing is visible<sup>(15)</sup>. General anaesthesia was induced with propofol, remifentanyl administered via target-controlled infusion (TCI) and succinylcholine (1 mg/kg). The duration of the complete intubation attempt was measured as the time from the end of face mask ventilation, until the appearance of the End-tidal CO<sub>2</sub> (EtCO<sub>2</sub>) waveform. In each group, procedures for intubation with a Macintosh laryngoscope or flexible fiberoptic laryngoscope were carried out according to those described by other authors<sup>(16-17)</sup>.

When these procedures failed with the Macintosh laryngoscope despite all manoeuvres, the patients were intubated using the flexible fiberoptic laryngoscope. If intubation was not possible with either technique, the patient was awakened and the intubation attempt has been declared failed. Complications due to nasal intubation were noted. During the tracheal intubation, standard monitoring, i.e. non-invasive arterial pressure measurement, heart rate and arterial oxygen saturation (pulse oximeter), was performed and the results were recorded before induction of anaesthesia and at the end of the intubation.

We considered the intubation time, success rate and laryngeal view of each intubation technique as the primary outcome variables for the expected easy and difficult intubation groups, respectively.

Hypotheses were tested using the  $\chi^2$  test (success rate of tracheal intubation, visualization of the glottis according to Cormack and Lehane) and t-test with a Bonferroni correction for multiple testing (intubation duration, vital signs and complications). Differences were considered significant for  $p < 0.05$ .

## Results

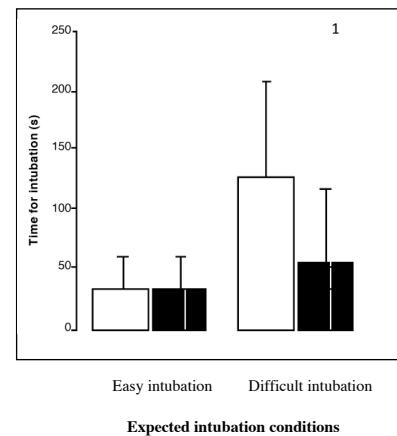
There was no significant differences regarding the anthropometric data of the patients, both groups and subgroups (Table 1).

	Easy intubation (n = 50 M/F = 0.92)		Difficult intubation (n = 50 M/F = 1.17)	
	Macintosh (n=26)	Flexible fiberoptic laryngoscope (n=24)	Macintosh (n=23)	Flexible fiberoptic laryngoscope (n=27)
Age; years	53 [21- 72]	46 [20- 78]	51 [19- 69]	56 [20- 75]
Weight; kg	69 [43- 95]	67 [45- 102]	70 [41- 110]	73 [48- 99]
Mallampati score; 1/2/3/4	11/12/0/0	12/15/0/0	0/0/11/14	0/0/10/15
Interincisor distance; mm	40 [35- 60]	38 [36- 52]	24 [16- 29]	24 [16- 30]

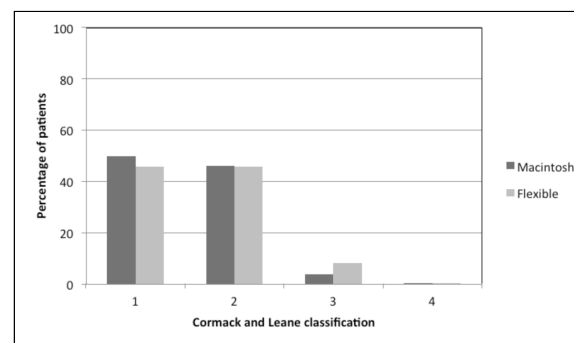
**Table 1:** Distribution within the two groups and related subgroups with regard to sex, age, weight, Mallampati score and interincisor distance. Values are median [range] or number.

The tracheas of all patients with an expected easy intubation were successfully intubated both with Macintosh technique and with flexible fiberoptic laryngoscope technique, whereas patients belonging to difficult intubation group have reported a success rates in Macintosh and flexible fiberoptic laryngoscope subgroups of, respectively, 26,1% (6/23) and 92,6% (25/27) ( $p < 0.01$ ). Among the 17 patients in whom intubation failed with the Macintosh laryngoscope, subsequent intubation with the flexible fiberoptic laryngoscope was successful. Of the two patients in whom intubation was not successful with the flexible fiberoptic laryngoscope was performed an elective tracheostomy using local anesthesia.

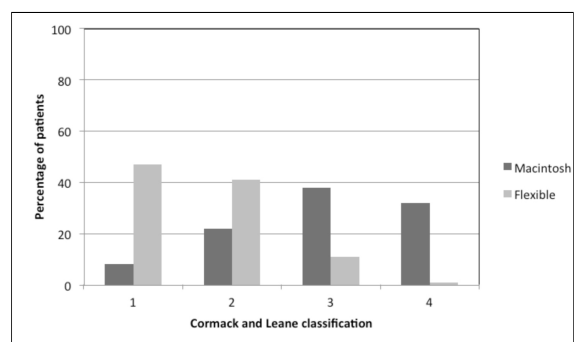
Time for intubation did not differ between the two techniques ( $p = 0.5$ , Fig. 1), as well as the view at the glottis according to the classification of Cormack and Lehane ( $p = 0.11$ ; Fig. 2) in patients with an expected easy intubation.



**Fig. 1:** Time for intubation using Macintosh (white bars) or flexible fiberoptic laryngoscope (black bars) in patients scheduled for tracheal intubation. Intubation time did not differ between the two techniques in expected easy intubation patients group ( $p = 0.5$ ), instead, it was significantly faster with the flexible fiberoptic laryngoscope for patients with expected difficult intubation ( $p < 0.01$ ).



**Fig. 2:** Percentage of patients according to the classification of Cormack and Lehane in expected easy intubation. The view at the glottis did not differ between the two techniques ( $p = 0.11$ ).



**Fig. 3:** Percentage of patients according to the classification of Cormack and Lehane in expected difficulty intubation. The view at the glottis was significantly better for the flexible fiberoptic laryngoscope ( $p < 0.01$ ).

For patients with expected difficulty in intubation, the view at laryngeal entrance according to Cormack and Lehane was significantly better for

the flexible fiberoptic laryngoscope than Macintosh laryngoscope ( $p < 0.01$ ; Fig. 3); further, in this group of patients, intubation with the flexible fiberoptic laryngoscope was significantly faster compared with intubation with a Macintosh ( $p < 0.01$ ; Fig. 1).

Time duration of intubation was analysed with and without inclusion of the failed attempts. When intubation duration was analysed excluding the failed attempts, intubation with the flexible fiberoptic laryngoscope was significantly faster [Macintosh 59 s (CI 45-71) vs flexible fiberoptic laryngoscope 33 s (CI 28-40);  $p=0.0059$ ]. When failed attempts were set at the time of the longest successful intubation (145 s), the results became even clearer [Macintosh 71 s (CI 44-86) vs flexible fiberoptic laryngoscope 35 s (CI 29-42);  $p = 0.00012$ ]. In this group of patients, where difficulty intubation was expected, trauma occurred during nasal intubation with the flexible fiberoptic laryngoscope on two patients which reported a mild epistaxis with no need for specific interventions, whereas in the Macintosh subgroup, six patients reported a dental trauma which required specific dental treatment ( $p = 0.15$ ).

In none of patients belonging to easy intubation group any trauma occurred. Flexible fiberoptic laryngoscope has caused a modest increases in blood pressure during intubation, but did not reveal any significant difference compared with direct laryngoscopy with the Macintosh laryngoscope between the intubation subgroups ( $p = 0.54$ ).

## Discussion

Operations that are conducted in the oral cavity or mandible, in which oral route is difficult or impossible e.g. temporomandibular joint ankylosis, trismus and where visualization of larynx by direct laryngoscopy is poor, the usage of a conventional laryngoscope may be extremely difficult or even impossible<sup>(18-19)</sup>. In addition, intra-oral and pharyngeal swelling and rigidity of the floor of mouth can further increase the intubation difficulty. Therefore, attempted tracheal intubation with a standard Macintosh laryngoscope under general anaesthesia in patients with odontogenic abscesses and a spread of the infection into facial or cervical spaces can lead to disastrous and life-threatening situations<sup>(11,20)</sup>. In such cases, the conventional fiber-optic nasal intubation method in which the nasal tube is inserted in one step after visualization of the vocal cords

by a flexible fiber-optic laryngoscope is the most valuable single tool available for the anaesthesiologist to facilitate difficult tracheal intubations<sup>(16)</sup>.

We have observed that the Macintosh and flexible fiberoptic laryngoscope were equally efficient for nasal intubation in patients who have no anticipated difficulty in intubation. For patients showing predictors of difficult orotracheal intubation, we have demonstrated that the flexible fiberoptic laryngoscope was superior to the Macintosh laryngoscope, resulting in a significantly better success rate, shorter time and better view of the glottis compared with a standard Macintosh laryngoscope.

Moreover, the tracheas of 73,9% of patients with an expected difficult intubation, that could not be intubated with a Macintosh laryngoscope, intubation with the flexible fiberoptic laryngoscope was feasible.

The main advantage of this nasal approach is a straight route to larynx and trachea so the endotracheal tube passes more easily. Another benefit of the nasal approach is the stability of the endotracheal tube once it has been secured in position. The main problem of nasal intubation is bleeding which can make the intubation difficult<sup>(16)</sup>.

Besides nasal bleeding, due to the nasopharyngeal advancement of the flexible scope and dental trauma during the use of Macintosh blade, no complications were found.

We have demonstrated in our study that the flexible fiberoptic laryngoscope significantly improved the view obtained of the glottis. This is certainly the main reason for the higher success rate for the flexible fiberoptic laryngoscope in the group of patients with an expected difficult intubation.

Moreover, as the flexible fiberoptic laryngoscope was associated with fewer situations than the Macintosh laryngoscope where it was required some supporting manoeuvres to optimise glottis exposure, the intubation time with this laryngoscope was shorter depending only by the time needed to advance the tube from the nasopharynx towards the glottis, without the use of any manoeuvres that may increase the intubation time.

Our study has several limitations. We limited our analysis to mouth opening and neglected other aspects that could indicate a difficult intubation such as rigidity of the floor of mouth, limited neck extension, blocked nostrils, drooling, or cellulitis affecting the anterior neck. Each of these criteria gives additional information about a potentially dif-

difficult intubation. However, these criteria are more difficult to quantify and not as reproducible as a simple measurement in millimeters. Therefore, we focused on the mouth opening and the comparison between the two intubation approaches without taking into account other different methods.

Overall, we conclude that in patients with odontogenic abscesses, tracheal intubation was performed significantly faster with a better view and a higher success rate with a flexible fiberoptic laryngoscope when compared with the Macintosh laryngoscope.

Most importantly, in cases where a difficult intubation is anticipated, we demonstrated that the flexible fiberoptic laryngoscope was more efficient for intubating the trachea than the Macintosh laryngoscope. Finally, in cases of failed intubation using the Macintosh laryngoscope, the flexible fiberoptic laryngoscope succeeded in almost 74% of the cases. Leading to a relevant improvement of intubation conditions and can be recommended for difficult airway management.

## References

- 1) Har-El G, Aroesty JH, Shaha A, Lucente FE. *Changing trends in deep neck abscess. A retrospective study of 110 patients.* Oral Surg Oral Med Oral Pathol, 1994; 77(5): 446-450.
- 2) Wang LF, Kuo WR, Tsai SM, Huang KJ. (2003) *Characterizations of life-threatening deep cervical space infections: a review of one hundred ninety-six cases.* Am J Otolaryngol, 2003; 24(2): 111-117.
- 3) Ryan P, McMahon G. *Severe dental infections in the emergency department.* Eur J Emerg Med, 2012; 19: 208-13.
- 4) Dhanrajani PJ, Jonaidel O. *Trismus: aetiology, differential diagnosis and treatment.* Dent Update, 2002; 29(2): 88-92,94.
- 5) Frerk CM. *Predicting difficult intubation.* Anaesthesia, 1991; 46: 1005-1008.
- 6) Wills PI, Vernon RP Jr. *Complications of space infections of the head and neck.* Laryngoscope, 1981; 91(7): 1129-1136.
- 7) Colmenero Ruiz C, Labajo AD, Yanez Vilas I, Paniagua J. *Thoracic complications of deeply situated serous neck infections.* J Craniomaxillofac Surg, 1993; 21(2): 76-81.
- 8) Haraden BM, Zwemer FL. *Descending necrotizing mediastinitis: complication of a simple dental infection.* Ann Emerg Med, 1997; 5: 683-686.
- 9) Suehara AB, Goncalves AJ, Alcadipani FA, Kavabata NK, Menezes MB. *Deep neck infection: analysis of 80 cases.* Braz J Otorhinolaryngol, 2008; 74(2): 253-259.
- 10) Huang TT, Liu TC, Chen PR, et al: *Deep neck infection: Analysis of 185 cases.* Head Neck, 2004; 26: 854.
- 11) Darshane S, Groom P, Charters P. *Responsive contingency planning: a novel system for anticipated difficulty in airway management in dental abscess.* Br J Anaesth, 2007; 99: 898-905.
- 12) Ovassapian A, Tuncbilek M, Weitzel EK, Joshi CW. *Airway management in adult patients with deep neck infections: a case series and review of the literature.* Anesth Analg, 2005; 100: 585-589.
- 13) Henderson JJ, Popat MT, Latto IP, Pearce AC. *Difficult Airway Society guidelines for management of the unanticipated difficult intubation.* Anaesthesia, 2004; 59: 675-94.
- 14) Samsoun GLT, Young JRB. *Difficult tracheal intubation: a retrospective study.* Anaesthesia, 1987; 42: 487-90.
- 15) Cormack RS, Lehane J. *Difficult tracheal intubation in obstetrics.* Anaesthesia, 1984; 39: 1105-11.
- 16) Ramesh S. *Fiberoptic airway management in adults and children.* Indian J Anaesth, 2005; 49(4): 293-9.
- 17) Batra YK, Mathew PJ. *Airway management with endotracheal intubation including awake intubation and blind intubation.* Indian J Anaesth, 2005; 49(4): 263-268.
- 18) Aoyama K, Takenaka I, Nagaoka E, Kadoya T. *Jaw thrust maneuver for endotracheal intubation using a fiberoptic stylet.* Anesth Analg, 2000; 90: 1457-8.
- 19) Hughes S, Smith JE. *Nasotracheal tube placement over the fiberoptic laryngoscope.* Anaesthesia, 1996; 51: 1026-8.
- 20) Heindel DJ. *Deep neck abscesses in adults. Management of the difficult airway.* Anesth Analg, 1987; 66: 774-6.

*Corresponding author*  
 CALOGERO GRILLO, MD  
 Policlinico-Vittorio Emanuele University  
 via Santa Sofia 78  
 95123 Catania  
 (Italy)