

## PERCUTANEOUS GASTROSTOMY PERFORMED WITH MAGNETIC TIPPED NASOGASTRIC TUBE: A NEW METHOD

AKCAN AKKAYA<sup>1</sup>, MUSTAFA SIT<sup>2</sup>, ABDULLAH DEMIRHAN<sup>1</sup>, MURAT BILGI<sup>1</sup>, UMIT Y TEKELIOGLU<sup>1</sup>, HASAN KOCOGLU<sup>3</sup>, HIKMET TEKCE<sup>4</sup>

<sup>1</sup>Abant Izzet Baysal University, Medical School, Department of Anesthesiology and Reanimation, Bolu - <sup>2</sup>Abant Izzet Baysal University, Medical School, Department of General Surgery, Bolu - <sup>3</sup>Abant Izzet Baysal University Medical School, Department of Anesthesiology and Reanimation, Bolu - <sup>4</sup>Abant Izzet Baysal University, Medical School, Department of Internal Medicine, Bolu, Turkey

### ABSTRACT

**Objectives:** Gastrostomy is an external route for long-term nutritional support, and there are complications related to gastrostomy, including peritonitis, organ injury, and bleeding. Endoscopic procedures require expensive equipment and a well-trained team. We designed an experimental study to evaluate the applicability of gastrostomy performed using a magnetic-tipped tube and an externally applied magnetic field in rats without need for endoscopic devices.

**Methodology:** Seven Wistar albino rats were used. A 6F feeding tube was reconfigured with a neodymium magnet (2x5 mm), and its proximal end was inserted into the stomach via an orogastric route. The prominence of the magnetic tip of the feeding tube was localized in the abdominal region of the rat using a strong, externally applied bigger magnet (2x5 cm). An incision was made at the point of prominence of the inner magnet, and the gastrostomy tube was placed. After the rats had been fed via gastrostomy for two days, they were examined using laparotomy.

**Results:** The gastrostomy accomplished with a magnetic-tipped tube and an externally applied magnetic field through the abdominal wall of rats with minimal incisions without any complications.

**Conclusion:** We recommend that this technique be developed in phylogenetically higher mammals than rats and eventually progress all the way up to human beings.

**Key words:** Gastrostomy, Magnetics, Enteral Nutrition, Rats, Endoscopy.

Received January 18, 2014; Accepted January 24, 2014

### Introduction

Gastrostomy is an invasive procedure undertaken to ensure long-term enteral nutrition in patients who have difficulty with the use of an oral route for feeding. Several methods have been described for the gastrostomy procedure, including laparoscopic- and fluoroscopy-guided techniques and endoscopic methods<sup>(1)</sup>. Although gastrostomy is a safe procedure, it brings a variety of major and minor complications that range from 4.9 to 50%. These complications could be due to anesthesia or surgery and include bleeding, leakage into the abdominal cavity, peritonitis, sepsis, and organ injury. Mortality rates range from 0.5 to 1.2%, while morbidity is 3 to 12%<sup>(1,2)</sup>.

Magnetic compression techniques for anastomosis have been used in the gastrointestinal system,

biliary tract, urinary tract, and for vascular anastomosis<sup>(3-9)</sup>.

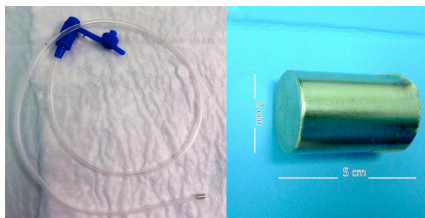
In this experimental study in rats, we aimed to report a new method named percutaneous magnetic gastrostomy, which could be faster, simpler, and easier to use in comparison with conventional methods.

### Materials and methods

The study began by obtaining 2012/37 numbered approval from the Abant Izzet Baysal University Board of Animal Research Ethics. During the first step of the procedure, a feeding tube with a small magnet attached to the tip would be inserted into the stomach of a rat. For the second stage, the magnetic tip of the feeding tube would be attracted with the help of an externally applied magnetic

force, which would cause the magnetic tip to rise to the abdominal wall. A small incision at the point of the raised abdominal wall would be made, and that part of the stomach would be pulled outside of the body. Eventually, the gastrostomy tube would be fixed to the protruding part of the gastric wall.

To implement this technique in rats, as shown in Figure 1a, a small cylindrical neodymium magnet (2x5 mm) was attached to the tip of a 6F feeding tube. To pinpoint the location of the magnetic tip of the tube introduced via an orogastric route into the rat's abdomen, a bigger and more powerful magnet (2x5 cm, Figure 2b) was prepared. The magnets were dipolar, chromium-plated, neodymium, iron, and boron alloy Nd2Fe14B type magnets.



**Figure 1a:** The feeding tube with the small magnet attached to its tip. **1b:** The magnet used to generate a strong magnetic field outside the abdomen.

The magnetic field strength of the magnets was measured while considering the distances in the laboratory of Abant İzzet Baysal University, Department of Physics, using a Leybold Didactic GmbH 51662 Gaussmeter (Table 1). Both magnets were attracted to each other from a distance of 53 mm.

| Distance (cm) | Magnetic field mT (mili Tesla) |               |
|---------------|--------------------------------|---------------|
|               | 2x5 mm magnet                  | 2x5 cm magnet |
| Contact       | 20                             | 105           |
| 1             | 3                              | 53            |
| 2             | 2                              | 23            |
| 3             | 1                              | 12            |
| 4             | 0                              | 6             |
| 5             | 0                              | 4             |
| 6             | 0                              | 3             |

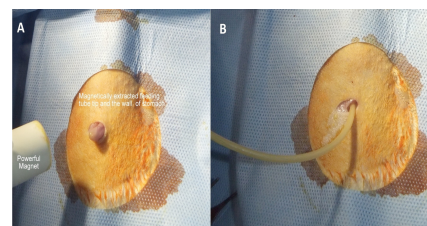
**Table 1:** The strengths and distance of the magnets used in the magnetic field.

Seven adult male Wistar albino rats with an average weight of 200 to 250 g were used in this study. The rats fasted overnight prior to the study but were given free access to water. All of the surgical and medical interventions in the experimental ani-

mals were performed under general anesthesia by the same team, and standard sterile conditions were observed. For all subjects, the doses of general anesthetics were 50 mg/kg dose of ketamine HCl (Ketalar 50 mg/ml, Eczacıbasi, Istanbul) intramuscularly and 5 mg/kg Xylazine (Rompun 20 mg/ml, Bayer, Istanbul) intramuscularly.

A bigger magnet with a strong magnetic field and dimensions of 2x5 cm was used to localize the feeding catheter with the magnetic tip in the abdominal cavity that had been inserted orogastrically. The tubercle formed by the inner tip of the feeding tube in the abdominal cavity as a response to the strong magnetic field was forced to move in a circular motion to minimize the likelihood of internal organ parts being caught between the abdominal and the gastric walls. Later, an incision of approximately 0.5 cm was made from the area of the tubercle on the abdominal wall, and the tip of the feeding tube was pulled out of the body by the force of the magnetic field (Fig. 2a).

A number 8 Foley catheter was inserted into the stomach, and the gastric and abdominal walls were taken up together and distended by inflating the balloon (Figure 2b). After that, 3/0 silk was used for fixation, and the gastrostomy was complete. The rats were fed with an enteral feeding solution via gastrostomy for two days, then re-laparotomy was performed. The rats were checked for leakage into the abdomen, perforation of the stomach, esophagus, spleen, liver, intestine, or vasculature, or any kind of organ injury. Complications attributable to the gastrostomy or to its location were evaluated. After laparotomy under anesthesia, the rats were sacrificed by administering high doses of anesthetic drugs.



**Figure 2a:** The gastric wall and magnetic tip of the feeding tube, which was extracted using the magnetic field to pull the tube from the abdominal wall incision. **2b:** Placed feeding tube.

## Results

Magnetic percutaneous gastrostomy was successfully performed in seven rats. There was no evidence of obstruction or signs of intolerance in any of the ani-

imals after the procedure. One rat died on the first day after the procedure. An autopsy was performed in that rat. Leakage was found in the abdominal cavity, but no signs of macroscopic peritonitis were seen. In the other rats, under general anesthesia and after providing the necessary sterility on the anterior abdominal wall, 4-cm incisions were made at midline for laparotomy. During the laparotomy, there were no signs of injury to the esophagus, stomach, spleen, liver, small intestine, colon, or vascular structures. Healthy rats had no evidence of peritoneal leakage or peritonitis. Normal saline had been given for a leak test, and no signs of leakage around the gastrostomy were identified. No internal organ herniation or compression between the stomach and the abdominal wall was observed.

## Discussion

Enteral nutrition is extremely beneficial, especially in the care and treatment of critically ill patients hospitalized in intensive care units. In patients with an intact gastrointestinal tract but difficulty with oral feeding, the enteral route should be used. There are different methods for enteral use, such as nasogastric tube, percutaneous fluoroscopic gastrostomy, open or laparoscopic gastrostomy, and percutaneous endoscopic gastrostomy<sup>(10)</sup>. Each of these methods, however, has its own complications, and there are other challenges, such as the necessity of skilled staff and complicated expensive equipment. Moreover, anesthesia-related events can be added these issues.

Cope et al. were the first to use intestinal magnets to create compression necrosis and produce anastomosis in animal subjects<sup>(3, 11)</sup>. Magnets have also been used for therapeutic purposes in different areas, such as the biliary and urinary tracts. Earlier experimental studies with magnets have been carried out in large animals, including pigs and dogs<sup>(3-9)</sup>. In a study conducted in rats using a magnet, magnetic compression gastrostomy (MCG) was performed<sup>(12)</sup>. The magnetic technique that we used in our study involved a feeding probe tipped with a neodymium magnet that could be detected and pulled out by a powerful magnet placed outside the abdominal wall. A small incision was made at the appropriate place to reach the feeding tube and then attached the stomach to produce a fistula to the skin. An 8 F-tipped balloon catheter was used in the rats as a permanent feeding tube.

Percutaneous endoscopic gastrostomy (PEG) was performed for the first time in 1980 according to

Gauderer and colleagues<sup>(13)</sup>. This method greatly facilitated the use and further development of the gastrostomy over time. However, PEG is a surgical procedure, so it requires an experienced surgical team and expensive, large, cumbersome endoscopic devices that are difficult to transfer from one place to another. This requirement in the absence of a specifically trained team and equipment necessitates the classical surgical technique, which increases costs and complications due to the anesthesia. Therefore, we developed a new method of magnetic percutaneous gastrostomy that would be cost effective and could be carried out by all intensive care physicians at the bedside with local anesthesia without the need for specific equipment. With this new method, the technological equipment required for the gastrostomy procedure would not be necessary, and the costs would be reduced as well.

The most serious complications related to PEG are bowel perforation and intra-abdominal organ injuries. Other complications include cardiopulmonary deterioration, aspiration, hemorrhage, and perforation, which have been observed at a rate of 0.005 to 0.01%<sup>(14)</sup>. In our study, there was one rat that had leakage into its abdominal cavity and no other complications. Mortality did not occur during the experiment. These findings suggest that the MPG method can be performed with a low complication rate. Patients who need gastrostomy are often intensive care patients, and these patients are more suitable for the PEG procedure than other gastrostomy methods that are more invasive.

Endoscopy laboratories can be far from intensive care units, and the transportation of endoscopic devices is another problem that may prevent the widespread use of this method. Additionally, possible malfunction of the expensive endoscopic devices due to transportation can increase the costs of the procedure. If gastrostomy with the help of a magnetic probe in humans can be achieved, costs, complications, and difficulties due to transportation will be avoided. Furthermore, this method is accessible to all physicians instead of only surgeons or gastroenterologists with experience in endoscopy, which will allow more patients who need this procedure to undergo it.

## Conclusions

In this experimental study, we demonstrated that a new method of gastrostomy with the help of a magnetically directed feeding tube can be successful-

ly and safely achieved using a minimal incision on the abdominal wall of a rat. This new gastrostomy technique will need to be developed in larger mammals to lead to its ultimate use in human patients.

## References

- 1) Frohlich T, Richter M, Carbon R, Barth B, Kohler H. *Review article: percutaneous endoscopic gastrostomy in infants and children*. *Aliment Pharm Ther*. 2010; 31(8): 788-801.
- 2) Connolly B, Krishnamurthy G, Amaral J. *Upper gastrointestinal access in children: techniques and outcomes*. *Techniques in Vascular and Interventional Radiology*. 2010; 13(4): 222-8.
- 3) Cope C. *Evaluation of compression cholecystogastric and cholecystojejunal anastomoses in swine after peroral and surgical introduction of magnets*. *Journal of Vascular and Interventional Radiology*. 1995; 6(4): 546-52.
- 4) Erdmann D, Sweis R, Heitmann C, et al. *Side-to-side sutureless vascular anastomosis with magnets*. *Journal of vascular surgery*. 2004; 40(3): 505-11.
- 5) Itoi T, Kasuya K, Sofuni A, et al. *Magnetic compression anastomosis for biliary obstruction: review and experience at Tokyo Medical University Hospital*. *Journal of hepato-biliary-pancreatic sciences*. 2011; 18(3): 357-65.
- 6) Myers C, Yellen B, Evans J, DeMaria E, Pryor A. *Using external magnet guidance and endoscopically placed magnets to create suture-free gastro-enteral anastomoses*. *Surgical endoscopy*. 2010; 24(5): 1104-9.
- 7) Pichakron KO, Jelin EB, Hirose S, et al. *Magnamosis II: magnetic compression anastomosis for minimally invasive gastrojejunostomy and jejunojejunostomy*. *Journal of the American College of Surgeons*. 2011; 212(1): 42-9.
- 8) Stepanov E, Erokhin A, Nikolaev V, Vasil'ev G, Mukho S. *Treatment of short urethral strictures in children using magnets*. *Urologiia i nefrologiia*. 1989(3): 8.
- 9) van Hoof JE, Vleggaar FP, Le Moine O, et al. *Endoscopic magnetic gastroenteric anastomosis for palliation of malignant gastric outlet obstruction: a prospective multicenter study*. *Gastrointestinal endoscopy*. 2010; 72(3): 530-5.
- 10) Beaver ME, Myers JN, Griffenberg L, Waugh K. *Percutaneous fluoroscopic gastrostomy tube placement in patients with head and neck cancer*. *Archives of Otolaryngology-Head & Neck Surgery*. 1998; 124(10): 1141.
- 11) Cope C, Clark TW, Ginsberg G, Habecker P. *Stent placement of gastroenteric anastomoses formed by magnetic compression*. *Journal of Vascular and Interventional Radiology*. 1999; 10(10): 1379-86.
- 12) Uygun I, Okur MH, Cimen H, et al. *Magnetic compression gastrostomy in the rat*. *Pediatric surgery international*. 2012; 28(5): 529-32.
- 13) Gauderer MW, Ponsky JL, Izant RJ. *Gastrostomy without laparotomy: a percutaneous endoscopic technique*. *Journal of pediatric surgery*. 1980; 15(6): 872-5.
- 14) Schrag SP, Sharma R, Jaik NP, et al. *Complications related to percutaneous endoscopic gastrostomy (PEG) tubes. A comprehensive clinical review*. *Journal of Gastrointestinal and Liver Diseases*. 2007; 16(4): 407.

## Acknowledgements

We would like to express our deepest appreciation to all those who provided us the possibility to complete this report. A special gratitude We give to Prof. Erol Ayaz and Vet.Med Ayhan Çetinkaya whose contribution, helped us to coordinate the processing of laboratory animals in all aspects.

## Request reprints from:

AKCAN AKKAYA MD  
Abant İzzet Baysal University, Medical School  
Department of Anesthesiology and Reanimation  
14280 Golkoy, Bolu  
(Turkey)