

AN UNUSUAL CAUSE OF ABDOMINAL MASS IN PREGNANCY: DOLICHOMEGACOLON

ZEHRA KURDOGLU¹, DENIZ DIRIK¹, MERTIHAN KURDOGLU¹, UMIT HALUK ILIKLERDEN²¹Yuzuncu Yil University, Faculty of Medicine, Department of Obstetrics and Gynecology, Van - ²Yuzuncu Yil University, Faculty of Medicine, Department of General Surgery, Van, Turkey**ABSTRACT**

Introduction: Dolichomegacolon is a clinical entity that may cause acute abdominal symptoms such as volvulus and ileus. In this case report, we present a pregnant woman with dolichomegacolon that mimics an abdominal mass.

Case: A 30-year-old woman was admitted to our clinic in active labor. We realized an abdominal mass in the abdomen 10 cm. in diameter. Abdominal ultrasound demonstrated a 12x10 cm sonolucent mass at the left side of the uterus. The patient had a history of previous cesarean sections, so she was delivered by cesarean section. On exploration, a 30-cm segment of descending colon was abnormally enlarged, with a width greater than 12 cm. The colon was waved aside, and a healthy newborn weighing 2850 g. was delivered by cesarean section with inferior transverse incision. The patient was discharged uneventfully on postoperative day 5.

Conclusion: Dolichomegacolon should be kept in mind as a possible benign cause of an abdominal mass in pregnant women presenting with abdominal mass.

Key words: abdominal mass, Dolichomegacolon

Received January 18, 2014; Accepted January 24, 2014

Introduction

The term “dolichomegacolon” refers to a clinical presentation that does not have a clear etiologic or pathophysiologic element. Megacolon is described as a colonic dilatation without any mechanical obstruction⁽¹⁾. Radiologically measured diameters of colonic segments more than 6.5 cm. in the rectosigmoid and descending colon, 8 cm. in the ascending colon and 12 cm. in the caecum are considered to be megacolon. Dolichomegacolon is characterized by an abnormally long and dilated colonic segment.

It is rarely seen in pregnant women with a few reported cases in the literature. Therefore, its incidence is not known exactly. Dolichomegacolon can present as congenital or idiopathic dolichomegacolon as well as intestinal pseudo-obstruction. Dolichomegacolon is a clinical diagnosis that the

etiology and risk factors are shown on Table 1.

| | |
|--|---|
| Hirschsprung disease | Amyloidosis |
| Chronic constipation | Hypothyroidism |
| Degenerative diseases of autonomic nervous system (Chagas disease) | Metabolic diseases |
| Acquired form of megacolon (Ogilvie Syndrome) | Scleroderma and other collagen diseases |
| Total colonic aganglionosis | Intestinal muscle disorders |
| Neurologic diseases | |
| Hydrocephalia | Diabetic neuropathy |
| Epilepsy | |
| Congenital brain trauma | |
| | Myotonic dystrophy |

Table 1: Etiology of dolichomegacolon.

Most of the patients have the acquired form of the disorder, while some of the cases are diagnosed with Hirschsprung disease. Classical Hirschsprung disease is 3 times more common in man than women and 90% of the cases are diagnosed in the newborn period. However, isolated hypoganglionosis which is one of the rarest subtypes of intestinal innervation disorders and a cause of megacolon can be diagnosed as late as 17 years old⁽²⁾.

In this case report, we present a pregnant woman with dolichomegacolon that mimics an abdominal mass in active labor.

Case

A 30-year-old G:6, P:2, A:3 woman was admitted to our clinic in active labor. We realized an abdominal mass 10 cm. in diameter. Abdominal ultrasound showed a 12x10-cm. sonolucent mass at the left side of the uterus. Fetal measurements were consistent with the 39th week of gestation. The patient had a history of cesarean section so she was delivered by cesarean section. On exploration, a 30-cm. segment of descending colon was abnormally enlarged, and its width was greater than 12 cm. (Figures 1 and 2).

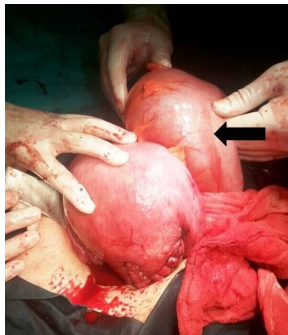


Figure 1: On exploration, arrow shows an enlarged colon at the posterior sight of the uterus.

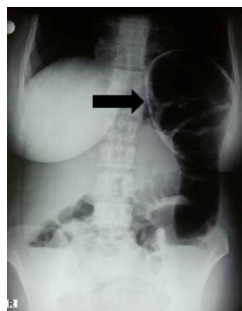


Figure 2: Arrow shows megacolon on plain abdominal radiograph (postoperative day 1).

The colon was waved aside, and a healthy newborn weighing 2850 g. was delivered by cesarean section with inferior transverse incision. The patient was consulted to a general surgeon intraoperatively. The descending colon was vital and normal peristaltic movements were seen; therefore, colectomy was not considered. Oral fluids were started on postoperative day 3 after the patient had gas discharge. The patient was discharged uneventfully on postoperative day 5, and a control in general surgery clinic after 1 month was recommended.

Discussion

Dolichomegacolon is usually diagnosed in young patients. The acquired type is more common in adults. This case was diagnosed incidentally during pregnancy without any symptoms. There was no clear etiology, so the diagnosis was considered to be idiopathic dolichomegacolon. Progesterone decreases the strength and frequency of bowel contractions and leads to increased bowel transit time in pregnancy⁽³⁾. Although we could not find an exact cause of dolichomegacolon in our case, it is possible that there may be a pathophysiological mechanism implicated with the effect of progesterone on colon.

During the last 5 decades, only 9 cases have been reported in the literature⁽⁴⁻¹²⁾. As with other types of abdominal mass, management of dolichomegacolon is an important clinical entity that can result in complications such as preterm labor, preterm premature rupture of membrane (PPROM), and dystocia^(4, 11). The differential diagnosis of abdominal mass in pregnancy is wide: malignant or benign ovarian tumors, bowel tumor, enlarged gallbladder, enlarged liver, enlarged spleen, fibroid uterus, and umbilical hernia. We saw enlarged bowel and easily differentiated other causes by ultrasound.

The timing and method of delivery are also important. According to the literature, preterm birth should be avoided in cases of dolichomegacolon⁽¹²⁾. Increased risk of dystocia should be considered when choosing delivery method. In cases of obstruction due to fecaloma, colonic decompression by hand can be attempted, but complications that may cause fetal distress, such as elongated operative time and uterine contractions, should be kept in mind^(11, 12). In the literature, fetal heart disorders have been reported in all cases that underwent colonic decompression by hand. If vaginal delivery is pre-

ferred, the fetus must be closely monitored. In this case, we preferred cesarean section due to a history of cesarean sections and the fact that the patient did not have any signs of fecaloma or obstruction in intraoperative exploration.

Conclusion

Dolichomegacolon is a rare condition in pregnancy that can mimic intraabdominal mass. Complications such as preterm labor, PPRM, and dystocia should be considered as well as the timing and method of delivery in the management of such cases.

References

- 1) Manuel DM, Piper MH, Gamarra RM, Ko CY. *Chronic Megacolon*, 2007.
- 2) Dingemann J, Puri P: *Isolated hypoganglionosis: systematic review of a rare intestinal innervation defect*. *Pediatr Surg Int* 2010, 26: 1111-1115.
- 3) Longo S.A, Moore R.C, Canzoneri B.J, Robichaux A. *Gastrointestinal conditions during pregnancy*. *Clin Colon Rectal Surg*. 2010; 23(2): 80-89.
- 4) Grasby ED, Higgins BK. *Megacolon in pregnancy causing dystocia*. *J Obstet Gynaecol Br Emp*. 1955; 62(6): 912-913.
- 5) Grossmann EM, Kaminski DL, Amon E, Longo WE. *Idiopathic megarectum complicating pregnancy: report of a case*. *Am J Gastroenterol*. 2000; 95(10): 2969-2972.
- 6) Resta P, Nardelli GB, Mincato C, De Bastiani BM. *Hirschsprung's disease and pregnancy: a case report*. *Eur J Obstet Gynecol Reprod Biol*. 1979; 9(1): 51-53.
- 7) Hjortrup A, Friis J, Mauritzen K. *Aggravation of untreated Hirschsprung's disease during pregnancy*. *Acta Obstet Gynecol Scand*. 1982; 61(4): 381-382.
- 8) Koskela O. *Megacolon complicating pregnancy*. *Ann Chir Gynaecol Fenn*. 1965; 54(3): 361-367.
- 9) Matsui T, Iwashita A, Iida M, Kume K, Fujishima M. *Acquired pseudo-obstruction of the colon due to segmental hypoganglionosis*. *Gastroentest Radio*. 1987; 12: 262-264.
- 10) Sheld HH. *Megacolon complicating pregnancy - a case report*. *J Reprod Med*. 1987; 32(3): 239-242.
- 11) Amorim J, Pinotti JA, Schapiro M, Casanova R. *Fecaloma in acquired megacolon as a factor in dystocia in labor - report of a case*. *Matern Infanc*. 1968; 26(4): 353-355.
- 12) Figueiredo A, Martins I, Palma F, Alves MJ, de Barros C. *Hypoganglionosis in pregnancy: a case report* *J Med Case Rep*. 2012; 6: 297.

Request reprints from:

ZEHRA KURDOGLU, M.D., Assoc. Prof.
Yuzuncu Yil Universitesi Tip Fakultesi
Kadin Hastaliklari ve Dogum Anabilim Dalı,
Dursun Odabas Tip Merkezi, Kampus
65080 Van
(Turkey)