

## A COMPARATIVE INVESTIGATION OF THE NEPHROTOXIC EFFECTS OF VARIOUS ANTIHYPERTENSIVE DRUGS IN RATS: BIOCHEMICAL AND HISTOPATHOLOGICAL ANALYSIS

ISMAIL MALKOC<sup>1</sup>, KONCA ALTUNKAYNAK<sup>2</sup>, MEHMET IBRAHIM TURAN<sup>3</sup>, NESRIN GURSAN<sup>4</sup>, AHMET HACIMUFTUOGLU<sup>5</sup>, FATIHA AKÇAY<sup>6</sup>, YILMAZ UCUNCU<sup>7</sup>, HALIS SULEYMAN<sup>8</sup>

<sup>1</sup>Ataturk University, Department of Anatomy, Erzurum - <sup>2</sup>Erzurum Research and Educational Hospital, Department of Biochemistry, Erzurum - <sup>3</sup>Research and Educational Hospital, Department of Pediatric Neurology, Diyarbakir - <sup>4</sup>Ataturk University, Department of Pathology, Erzurum - <sup>5</sup>Ataturk University, Department of Pharmacology, Erzurum - <sup>6</sup>Ataturk University, Department of Biochemistry, Erzurum - <sup>7</sup>Recep Tayyip Erdogan University, Department of Anatomy, Rize - <sup>8</sup>Recep Tayyip Erdogan University, Department of Pharmacology, Rize, Turkey

### ABSTRACT

**Aims:** Hypertension is known to cause potentially fatal kidney damage. However, it is unclear whether long-term use of antihypertensive drugs establishes any toxic effect on the kidney. This study investigate whether clonidine, methylodopa, rilmenidine, amlodipine and ramipril establish nephrotoxic effects in rats.

**Materials and methods:** Methylodopa, clonidine, rilmenidine, amlodipine and ramipril were administered orally to rat groups for three months. At the end of that period, rats were sacrificed by decapitation, the kidneys extracted and biochemical and histopathological analyses performed.

**Results:** The experimental results revealed that methylodopa and ramipril slightly increased Malondialdehyde (MDA) and Myeloperoxidase (MPO) levels in rat kidney tissue and slightly reduced total glutathione (GSH). Rilmenidine increased MDA and MPO levels more than methylodopa and ramipril, but less than clonidine and amlodipine. Severe glomerular cellularity, hyalinization, tubulointerstitial inflammation and tubular necrosis were encountered in the clonidine and amlodipine groups, in which MDA and MPO were highest and GSH lowest. These histopathological findings were moderate in the rilmenidine group and mild in the methylodopa and ramipril groups. In addition to these histopathological findings, mild interstitial fibrosis and increased mesenchymal matrix were observed in the amlodipine group and increased mesenchymal matrix alone in the clonidine group.

**Conclusions:** Ramipril and methylodopa were identified as drugs causing mild nephrotoxicity, rilmenidine moderate nephrotoxicity and amlodipine and clonidine severe nephrotoxicity.

**Key words:** Antihypertensive agents, kidney, toxicity, rat.

Received January 18, 2014; Accepted January 24, 2014

### Introduction

Many drugs are used in the treatment of hypertension, including clonidine, methylodopa, rilmenidine, ramipril and amlodipine<sup>(1)</sup>. It's known that hypertension is able to determine multiple organs damage including heart, eyes, kidneys and other organs, requiring, therefore, long-term treatment. Forty-two percent of hypertension complications are reported to involve the kidney, and the death rate associated with this is about 10-15%<sup>(2)</sup>. Investigation and identification of the side-effects on the kidney of antihypertensive may be useful in

determining indications and contraindications in kidney disorder accompanying hypertension. The problems encountered in clinical practice are organ toxicity appearing during drug use for several reasons. Therefore it is important identify the possible nephrotoxic effects of these drugs, to determine the adequate dose-adjustment.

Biochemical and histopathological tests are used in order to reveal the toxic effects of drugs. While oxidant/antioxidant parameters and organ functions are determined using biochemical tests, structural toxic effects in tissues are determined with histopathological examinations<sup>(3)</sup>. Tissue

integrity is assessed using the difference in the oxidant/antioxidant balance. Various aggressive factors that can lead to tissue damage impair that balance in favor of oxidants<sup>(4)</sup>. Tok A et al. reported that oxidant parameters such as Malondialdehyde (MDA) and Myeloperoxidase (MPO) rose and total glutathione (GSH), an antioxidant parameter, decreased in renal ischemia/reperfusion injury<sup>(5)</sup>. Girardi et al. showed that structural damage such as glomerular cellularity developed in the kidney with the administration of toxic substances<sup>(6)</sup>. Glomerular cellularity is a pathological marker of nephritis<sup>(7)</sup>. El-Gerbed MS identified ultrastructural changes such as thickening of the glomerular basal membrane in kidney damage induced with deltamethrin<sup>(8)</sup>. Structural impairments such as hyalinization, tubulointerstitial inflammation, glomerulosclerosis, tubular necrosis, interstitial fibrosis and increased mesenchymal matrix can be seen in kidney tissue damage<sup>(9-13)</sup>. Methyldopa, clonidine, rilmenidine, amlodipine and ramipril have been shown to exhibit biochemical and structural toxic effects at differing levels in the rat liver<sup>(3)</sup>. However, our literature review revealed no comparative research into the biochemical and structural nephrotoxic effects emerging in animals in association with long-term use of methyldopa, clonidine, rilmenidine, amlodipine and ramipril.

The purpose of this study was therefore to investigate and compare the biochemical and structural nephrotoxic effects developing in rats in association with long-term use of methyldopa, clonidine, rilmenidine, amlodipine and ramipril.

## Materials and methods

### Animals

Sixty albino Wistar rats weighing 200-210 g were obtained from the Ataturk University Medicinal and Experimental Application and Research Center, Erzurum, Turkey. Animals were allowed 14 days to acclimatize before the experiments commenced. They were kept in a 12:12 h light/dark cycle (lights on 07:00 - 19:00 h) in an air-conditioned constant temperature ( $22 \pm 1$  °C) colony room, with free access to water and 20% (w/w) protein commercial chow. All studies were performed in accordance with the ethical guidelines set out by the local ethical committee that were fully compatible with the "NIH Guide for the Care and Use of Laboratory Animals".

### Chemical Substances

All biochemical assay compounds were purchased from the following sources: Zdorove Drug, Ukraine (clonidine); Eczacıbaşı Drug, Turkey (methyldopa); Pfizer Drug, Turkey (amlodipine); Aventis Drug, Turkey (ramipril); Servier Pharmaceuticals, France (rilmenidine).

### Administration of clonidine, methyldopa, rilmenidine, amlodipine and ramipril.

The animals in the experiment were randomly assigned into six groups of 10 rats each. Clonidine was administered at a dose of 0.075 mg/kg, methyldopa at 100 mg/kg, rilmenidine at 0.5 mg/kg, amlodipine at 2 mg/kg and ramipril at 2 mg/kg, all once a day, orally, over a period of 3 months. Control group healthy rats were given the same volume of distilled water as solvent. At the end of that period rats were sacrificed by decapitation. The kidneys were subsequently extracted and biochemical and histopathological examinations were performed. The biochemical and histopathological results from the drug groups were then compared with those from the healthy control group.

### Biochemical analyses

#### Determination of Malondialdehyde (MDA) formation

The concentrations of tissue lipid peroxidation were determined by estimating MDA using the thiobarbituric acid test<sup>(14)</sup>. In brief, the rat kidneys were promptly excised and rinsed with cold saline. To minimize the possibility of interference of hemoglobin with free radicals, blood adhering to the tissue was carefully removed. The tissue was weighed, and homogenized in 10 mL of 100 g/L KCl. The homogenate (0.5 mL) was added to a solution containing 0.2 mL of 80 g/L sodium lauryl sulphate, 1.5 mL of 200 g/L acetic acid, 1.5 mL of 8 g/L 2-thiobarbiturate and 0.3 mL distilled water. The mixture was incubated at 98 °C for 1 h. Upon cooling, 5 mL of n-butanol:pyridine (15: 1) was added. The mixture was vortexed for 1 min and centrifuged for 30 min at 4,000 rpm. The absorbance of the supernatant was measured at 532 nm.

#### Determination of Myeloperoxidase (MPO) activity

MPO activity was measured according to the modified method of Bradley et al<sup>(15)</sup>. The homogenized samples were frozen and centrifuged at 1,500 g for 10 min at 4 °C. MPO activity in the super-

natant was determined by adding 100 mL of the supernatant to 1.9 mL of 10 mmol/L phosphate buffer (pH 6.0) and 1 mL of 1.5 mmol/L 0-dianisidine hydrochloride containing 0.0005% (wt/vol) hydrogen peroxide. The changes in absorbance at 450 nm of each sample were recorded on a UV-vis spectrophotometer

#### **Total glutathione (tGSH) determination**

The amount of GSH in tissue was measured according to the method described by Sedlak & Lindsay<sup>(16)</sup>. The tissue surface of the kidney was collected, weighed and then homogenized in 2 mL 50 mM Tris-HCl buffer containing 20 mM EDTA and 0.2 mM sucrose, pH 7.5. The homogenate was immediately precipitated with 0.1 mL of 25 % trichloroacetic acid, and the precipitate was removed by centrifugation at 4,200 rpm for 40 min at 4 °C. The supernatant was used to determine GSH using 5,5'-dithiobis 2-nitrobenzoic acid. Absorbance was measured at 412 nm using a spectrophotometer.

#### **Creatinine and blood urea nitrogen measurement**

Venous blood samples were collected from tail vein into tubes without anticoagulant. Serum was separated by centrifugation after clotting and stored at -80°C until assayed. Creatinine and urea levels were determined in a Cobas 8000 (Roche) spectrophotometric system using the colorimetric method. Blood urea nitrogen (BUN) levels were calculated from the formula  $BUN = Urea \times 0.48$ . In alkaline solution, creatinine forms a yellow/orange complex with picrate. The color intensity is directly proportional to the creatinine concentration and can be measured by the photometric method (at 505 nm). Assays using rate-blanking minimize interference by bilirubin. Serum samples contain proteins which react non-specifically according to the Jaffe method. Serum results must be corrected by 0.3 mg/dL (26 µmol/L) to obtain accurate values. This correction causes a measurement error of 1% in urine specimens because these do not contain non-specific proteins. Urea is hydrolyzed by urease to form CO<sub>2</sub> and ammonia. The ammonia formed then reacts with α-ketoglutarate and Nicotinamide adenine dinucleotide (NADH) in the presence of glutamate dehydrogenase to yield glutamate and NAD<sup>+</sup>. The decrease in absorbance due to consumption of NADH is measured kinetically. The NADH complex to decrement is determined by the photometric

method (at 340 nm).

#### **Histopathological examination**

The specimens were fixed in 10 % formalin and routinely processed for paraffin embedding. For the evaluation, 4 µm thick sections were obtained from each sample and stained with hematoxylin-eosin. At microscopic examination, glomerular cellularity, hyalinization, tubular inflammation, tubular necrosis, increase of in mesenchymal matrix, glomerular basement membrane thickening, glomerulosclerosis and interstitial fibrosis were evaluated in 10 separate microscopic fields from two sections. These were scored from 0 to 3.

#### **Statistical analyses**

All data were subjected to one-way analysis of variance using Statistical Package for Social Sciences 18.0 (Armonk, NY, USA) software. Differences among groups were obtained using the Tukey option, and significance was set at  $P \leq 0.05$ . The results are expressed as mean ± standard error of the mean (SEM).


## **Results**

#### **Biochemical findings**

##### **MDA, MPO and GSH measurement results**

A statistically significant difference was determined between MDA, MPO and tGSH levels when all the groups were compared together ( $P < 0.05$ ). As shown in Figure 1, MDA levels in kidney tissue in the methyl dopa, clonidine, rilmenidine, amlodipine, ramipril and control animals were  $2.4 \pm 0.2$  ( $P > 0.05$  when compared with the control group),  $4.0 \pm 0.2$  ( $P < 0.05$  when compared with the control group),  $3.5 \pm 0.1$  ( $P < 0.05$  when compared with the control group),  $4.3 \pm 0.2$  ( $P < 0.05$  when compared with the control group),  $2.6 \pm 0.2$  ( $P > 0.05$  when compared with the control group) and  $2.2 \pm 0.4$  µmol/g protein, respectively. MPO activity was measured at  $3.3 \pm 0.7$  ( $P > 0.05$  when compared with the control group),  $9.5 \pm 0.7$  ( $P < 0.05$  when compared with the control group),  $7.5 \pm 0.9$  ( $P < 0.05$  when compared with the control group),  $9.7 \pm 0.9$  ( $P < 0.05$  when compared with the control group),  $3.5 \pm 0.7$  ( $P > 0.05$  when compared with the control group) and  $2.2 \pm 0.5$  U/g, respectively (Figure 2). GSH levels for these groups were  $4.8 \pm 0.6$  ( $P > 0.05$  when compared with the control group),  $2.3 \pm 0.5$  ( $P < 0.05$  when compared with the control group),  $3.3 \pm 0.7$  ( $P > 0.05$  when compared with the control group),  $2.2 \pm 0.4$  ( $P < 0.05$  when


compared with the control group),  $5.0 \pm 0.6$  ( $P > 0.05$  when compared with the control group) and  $5.2 \pm 0.7$  nmol/g protein (Figure 3).



**Figure 1:** Comparison of group in terms of Malondialdehyde (MDA) levels.

Notes: One-way analysis of variance post hoc Tukey test was performed. MDA levels defined in µmol/g protein. Bars are means ± Standard error mean.

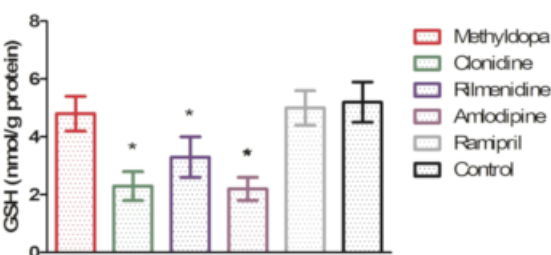
\*  $P < 0.05$  was significant, compared versus control groups



**Figure 2:** Comparison of group in terms myeloperoxidase (MPO) levels.

Notes: One-way analysis of variance post hoc Tukey test was performed. MPO levels defined in U/g protein. Bars are means ± Standard error mean.

\*  $P < 0.05$  was significant, compared versus control groups



**Figure 3:** Comparison of group in terms total glutathione (GSH) levels.

Notes: One-way analysis of variance post hoc Tukey test was performed. GSH levels defined in nmol/g protein. Bars are means ± Standard error mean.

\*  $P < 0.05$  was significant, compared versus control groups

**Blood BUN and creatinine results**

A statistically significant difference was determined among BUN and creatinine levels among the study groups ( $P < 0.05$ ). Mean blood BUN levels in rats receiving methyldopa, clonidine, rilmenidine,

amlodipine and ramipril were, respectively,  $34 \pm 3$  ( $P > 0.05$  when compared with the control group),  $200 \pm 6$  ( $P < 0.05$  when compared with the control group),  $116 \pm 5$  ( $P < 0.05$  when compared with the control group) and  $36 \pm 3$  mg/dL ( $P > 0.05$  when compared with the control group) and  $26 \pm 2$  mg/dL in the control group. Blood creatinine levels for these groups were  $0.43 \pm 0.03$  ( $P > 0.05$  when compared with the control group),  $2.2 \pm 0.2$  ( $P < 0.05$  when compared with the control group),  $1.3 \pm 0.1$  ( $P < 0.05$  when compared with the control group),  $2.2 \pm 0.2$  ( $P < 0.05$  when compared with the control group),  $0.51 \pm 0.04$  ( $P > 0.05$  when compared with the control group) and  $0.36 \pm 0.03$  mg/dL .

**Histopathological findings**

The results of the microscopic examinations of kidney tissues of rats given methyldopa, clonidine, rilmenidine, amlodipine and ramipril are given in Table 1 and Figure 4.

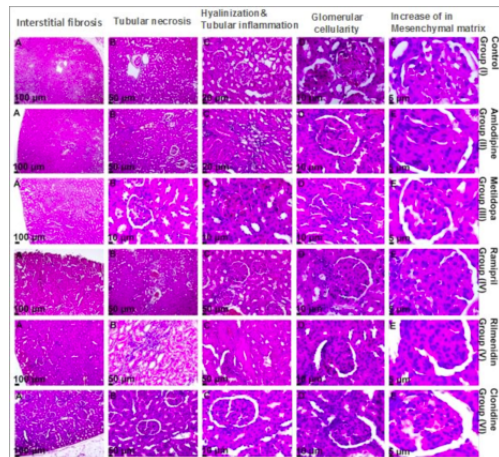
Groups	Methyldopa	Clonidine	Rilmenidine	Amlodipine	Ramipril	Control
Histopathology						
Glomerular cellularity	+	+++	+	+++	+	0
Hyalinization	+	+++	++	+++	+	0
Tubulointerstitial inflammation	+	+++	++	+++	+	0
Tubular necrosis	+	+++	++	+++	+	0
Interstitial fibrosis	0	0	0	+	0	0
Increased mesenchymal matrix	0	+	0	+	0	0
Total injury	4	13	7	14	4	0

**Table 1:** Microscopic examination results of rat kidney tissue given methyldopa, clonidine, rilmenidine, amlodipine and ramipril.

Note: 0 normal tissue, + mild injury, ++ moderate injury, +++ severe injury.

**Control group kidney tissue**

Microscopically, the healthy control group kidney tissue had a normal histological appearance, and no pathological findings were observed.



**Figure 4:** Histopathological findings of groups.

#### ***Methyldopa group kidney tissue***

Mild glomerular cellularity, hyalinization, tubulointerstitial inflammation and tubular necrosis were observed in the rat kidney tissue receiving methyldopa. No pathological findings such as interstitial fibrosis or increased mesenchymal matrix were encountered.

#### ***Clonidine group kidney tissue***

Severe glomerular cellularity, hyalinization, tubulointerstitial inflammation and tubular necrosis and mildly increased mesenchymal matrix were observed in kidney tissue receiving clonidine. No interstitial fibrosis was seen.

#### ***Rilmenidine group kidney tissue***

Mild glomerular cellularity, moderate hyalinization and severe tubular necrosis were observed in the rat group given rilmenidine. No pathological findings such as interstitial fibrosis or increased mesenchymal matrix were observed.

#### ***Amlodipine group kidney tissue***

Severe glomerular cellularity, hyalinization, tubulointerstitial inflammation, tubular necrosis and mildly increased mesenchymal matrix and interstitial fibrosis were observed in the kidney tissue of rats given amlodipine.

#### ***Ramipril group kidney tissue***

Mild glomerular cellularity, hyalinization, tubulointerstitial inflammation and tubular necrosis were observed in kidney tissue of rats given ramipril.

## **Discussion**

This study investigated and compared the biochemical and structural nephrotoxic effects associated with long-term drug use in rats given methyldopa, clonidine, rilmenidine, amlodipine and ramipril (MCRAR). Biochemical examinations revealed different degrees of increases in MDA and MPO levels and a decrease in GSH levels in kidney tissues of rats receiving MCRAR compared to those of the control group. A previous study of ours revealed that levels of the oxidant parameters MDA and MPO in liver tissue of rats receiving MCRAR increased to varying extents compared to a healthy control group while levels of the antioxidant GSH decreased<sup>(3)</sup>. In another study of ours, we determined a significant rise in MDA and MPO levels and a significant decrease in GSH levels in nephrotoxicity induced in rats with cisplatin<sup>(12)</sup>. Clonidine and amlodipine have been reported to induce severe damage in liver tissue, rilmenidine moderate damage and methyldopa and ramipril mild damage<sup>(3)</sup>. Salman S et al. showed that MCRAR produced similar effects in rat ovarian tissue<sup>(17)</sup>. Various toxic substances (aggressive factors) that can lead to tissue damage are known to impair the oxidant/antioxidant balance in favor of oxidants<sup>(4)</sup>. The findings from our study are compatible with the information from the literature. Elevated blood BUN and creatinine levels were determined in groups with high MDA and MPO and low GSH levels. Sener MT et al. reported a significant increase in blood BUN and creatinine levels in nephrotoxicity induced in rats with cisplatin<sup>(12)</sup>. Domitrović R et al. also reported an increase in BUN and creatinine levels in cisplatin-related nephrotoxicity<sup>(18)</sup>. These data from the literature indicate that a rise in BUN and creatinine levels is a significant marker of nephrotoxicity.

MDA and MPO are important oxidative stress markers. Histopathological injury such as glomerular cellularity, hyalinization, tubulointerstitial and tubular necrosis was more pronounced in the clonidine and amlodipine groups, in which these oxidant parameters were also elevated. Histopathological examination has shown that toxic substances causes glomerular cellularity (hypercellularity) in the kidneys<sup>(19)</sup>. Pathological symptoms such as glomerular cellularity, hyalinization and tubular necrosis have also been reported to appear in kidney tissue in long-term exposure to the effect of lead<sup>(20)</sup>. In addition, tubulointerstitial inflammation has been reported to develop in animal kidney tissue exposed

to oxidative stress, and to be prevented with antioxidant therapy<sup>(21)</sup>. Interstitial fibrosis was encountered in the amlodipine group, in which there was pronounced tubulointerstitial inflammation. Interstitial fibrosis is known to be seen in chronic kidney diseases<sup>(22)</sup>. Moreover, MPO activity in clonidine and amlodipine group kidney tissue, in which tubulointerstitial inflammation was pronounced, was higher compared to the other groups. MPO is present in active polymorphonuclear leukocytes (PNLs), known as proinflammatory cells. Activation of PNLs causes excess production of superoxide, hydrogen peroxide and hydroxyl radicals, in addition to MPO. Reaction of these radicals with MPO leads to the formation of products that cause more severe tissue damage, such as hypochloric acid and N-chloramine<sup>(23)</sup>.

In conclusion, the MCRARs used in the experiment led to varying degrees of toxic effect in kidney tissue. Long-term use of these drugs led to differing degrees of functional and pathological impairments in the kidneys. Ramipril and methyldopa were distinguished as drugs causing mild nephrotoxic effects, rilmenidine as causing moderate effects and amlodipine and clonidine as causing severe effects. This information indicates that clonidine and amlodipine should not be used in patients with glomerular cellularity, hyalinization, tubulointerstitial inflammation and tubular necrosis. They also reveal that hyalinization, tubulointerstitial inflammation and tubular necrosis are contraindications for rilmenidine. Methyldopa and ramipril should be used in a controlled manner in kidney patients.

## References

- 1) Brunton LL. Goodman and Gilman's *The Pharmacological Basis of Therapeutics*.: The McGraw-Hill Companies; 2010.
- 2) Perera GA. *Hypertensive vascular disease; description and natural history*. J Chronic Dis. 1955; 1: 33-42.
- 3) Malkoc I, Cetin N, Altuner D, Hacımuftuoğlu A, Gursan N, Bakan E, et al. *Comparative Review of Biochemistry and Cell Anatomy of the Hepatic Tissue in Rats Administered Some Anti Hypertensive Drug for a Long time*. Lat Am J Pharm. 2012; 31: 537-44.
- 4) Kisaoglu A, Borekci B, Yapca OE, Bilen H, Suleyman H. *Tissue Damage and Oxidant/Antioxidant Balance*. Eurasian J Med. 2013; 45: 47-9.
- 5) Tok A, Sener E, Albayrak A, Cetin N, Polat B, Suleyman B, et al. *Effect of mirtazapine on oxidative stress created in rat kidneys by ischemia-reperfusion*. Ren Fail. 2012; 34: 103-10.
- 6) Girardi G, Elias MM. *Verapamil protection against mercuric chloride-induced renal glomerular injury in rats*. Toxicol Appl Pharmacol. 1998; 152: 360-5.
- 7) Ono T, Kamikado K, Morimoto T. *Protective effects of Shichimotsu-koka-To on irreversible Thy-1 nephritis*. Biol Pharm Bull. 2013; 36: 41-7.
- 8) El-Gerbed MS. *Protective effect of lycopene on deltamethrin-induced histological and ultrastructural changes in kidney tissue of rats*. Toxicol Ind Health. 2012;
- 9) Chen YH, Liang YX, Chen LQ, Lu YM, Liang JJ, Zhang J, et al. *Nephrotoxicity of tacrolimus and preventive effect of diltiazem: experiment with rats*. Zhonghua Yi Xue Za Zhi. 2009; 89: 704-8.
- 10) Hu L, Yang C, Zhao T, Xu M, Tang Q, Yang B, et al. *Erythropoietin ameliorates renal ischemia and reperfusion injury via inhibiting tubulointerstitial inflammation*. J Surg Res. 2012; 176: 260-6.
- 11) Hornigold N, Johnson TS, Huang L, Haylor JL, Griffin M, Mooney A. *Inhibition of collagen I accumulation reduces glomerulosclerosis by a Hic-5-dependent mechanism in experimental diabetic nephropathy*. Lab Invest. 2013; 93: 553-65.
- 12) Sener MT, Sener E, Tok A, Polat B, Cinar I, Polat H, et al. *Biochemical and histologic study of lethal cisplatin nephrotoxicity prevention by mirtazapine*. Pharmacol Rep. 2012; 64: 594-602.
- 13) Zhou Y, Xu H, Xu W, Wang B, Wu H, Tao Y, et al. *Exosomes released by human umbilical cord mesenchymal stem cells protect against cisplatin-induced renal oxidative stress and apoptosis in vivo and in vitro*. Stem Cell Res Ther. 2013; 4: 34.
- 14) Ohkawa H, Ohishi N, Yagi K. *Assay for lipid peroxides in animal tissues by thiobarbituric acid reaction*. Anal Biochem. 1979; 95: 351-8.
- 15) Bradley PP, Priebe DA, Christensen RD, Rothstein G. *Measurement of cutaneous inflammation: estimation of neutrophil content with an enzyme marker*. J Invest Dermatol. 1982; 78: 206-9.
- 16) Sedlak J, Lindsay RH. *Estimation of total, protein-bound, and nonprotein sulfhydryl groups in tissue with Ellman's reagent*. Anal Biochem. 1968; 25: 192-205.
- 17) Salman S, Kumbasar S, Yilmaz M, Kumtepe Y, Borekci B, Bakan E, et al. *Investigation of the effects of the chronic administration of some antihypertensive drugs on enzymatic and non-enzymatic oxidant/antioxidant parameters in rat ovarian tissue*. Gynecol Endocrinol. 2011; 27: 895-9.
- 18) Domitrovic R, Cvijanovic O, Pugel EP, Zagorac GB, Mahmutefendic H, Skoda M. *Luteolin ameliorates cisplatin-induced nephrotoxicity in mice through inhibition of platinum accumulation, inflammation and apoptosis in the kidney*. Toxicology. 2013; 310: 115-23.
- 19) Abdu S, Ali A, Ansari S. *Cytotoxic effect of ochratoxin A on the renal corpuscles of rat kidney: could ochratoxin A cause kidney failure?* Histol Histopathol. 2011; 26: 543-9.
- 20) Jarrar BM. *Histological and histochemical alterations in the kidney induced by lead*. Ann Saudi Med. 2003; 23: 10-5.
- 21) An WS, Kim HJ, Cho KH, Vaziri ND. *Omega-3 fatty acid supplementation attenuates oxidative stress, inflammation, and tubulointerstitial fibrosis in the remnant kidney*. Am J Physiol Renal Physiol. 2009; 297:

- F895-903.
- 22) Guo J, Wu W, Sheng M, Yang S, Tan J. *Amygdalin inhibits renal fibrosis in chronic kidney disease*. Mol Med Rep. 2013; 7: 1453-7.
- 23) Karmeli F, Okon E, Rachmilewitz D. *Sulphydryl blocker induced gastric damage is ameliorated by scavenging of free radicals*. Gut. 1996; 38: 826-31.

---

Request reprints from:  
MEHMET İBRAHİM TURAN  
Department of Pediatric Neurology  
Research and Educational Hospital  
Diyarbakir  
(Turkey)