

## MULTIDISCIPLINARY APPROACH IN THE REMOVAL OF POST-TRAUMA FOREIGN BODIES IN THE HEAD AND NECK DISTRICT: CASES REPORT AND REVIEW OF LITERATURE

FRANCESCO FREN<sup>1</sup>, BRUNO GALLETTI<sup>1</sup>, ROCCO BRUNO<sup>1</sup>, FRANCESCO MARTINES<sup>2</sup>, PIETRO ABITA<sup>1</sup>, FRANCESCO GAZIA<sup>1</sup>, FEDERICO SIRECI<sup>1,3</sup>, FRANCESCO GALLETTI<sup>1</sup>

<sup>1</sup>Department of Adult and Development Age Human Pathology “Gaetano Barresi”, unit of otorhinolaryngology, University of Messina, Italy - <sup>2</sup>University of Palermo, Bio.Ne.C. Department, ENT Section, Palermo Italy - <sup>3</sup>ENT Section, ARNAS Fatebenefratelli Hospital, Palermo Italy

### ABSTRACT

**Introduction:** The management of foreign bodies (FBs) penetrating the head and neck district is a condition rare but at risk for the patient's life because this district is particularly rich in vital structures. Therefore, their management requires a multidisciplinary approach.

**Materials and methods:** In this study we retrospectively examine two emblematic cases among 183 that occurred in our hospital from January 2008 to December 2017.

**Results:** There were 183 cases of FBs of the head and neck district submitted to extraction with a range of age of between 18 months old and 79 years old. Of 183 patients, 112 were children, 60 were adults. The incidence was prevalent among children, with 112 cases against 60 cases in adults (including 11 post-dental care cases). Only 2 remaining cases described are characterized by the involvement of several districts

**Conclusion:** Both cases evidenced like as a multidisciplinary approach is important to minimize potential complications and sequelae

**Keywords:** foreign bodies, emergency, multidisciplinary approach, multidistrict.

DOI: 10.19193/0393-6384\_2019\_1\_66

Received July 17, 2018; Accepted September 20, 2018

### Introduction

The management of foreign bodies (FBs) penetrating the head and neck district is a condition rarely reported in Literature. Since this district is particularly rich in vital structures, the penetration of a FB at this level often put at risk the patient's life<sup>(1)</sup>. Therefore, their management requires a multidisciplinary approach that can involve, in addition to anaesthetists, radiologists and otolaryngologists, also ophthalmologists, vascular surgeons, maxillo-facial surgeons and sometimes neurosurgeons and interventional radiologist. With an isolated involvement of the nasal cavities, the paranasal sinuses and the base of the skull, the endoscopic sinus surgery

(ESS) is the most accurate strategy to perform a safe and accurate removal of FBs<sup>(2,3,4)</sup>; however, the involvement of the surrounding compartments (neck, pharynx, skull base, brain, orbit) requires a multidisciplinary approach, mainly due to the presence of both vascular and nervous critical structures<sup>(5,6,7,8,9)</sup>.

Surgery, if the conditions allow it, must be preceded by an accurate preoperative evaluation. The aim of this evaluation, which can be different in every specific case according to the site and the type of FB, is to minimize the incidence of complications and to avoid incomplete removal because of the inability to accurately locate the FB. Contrast-enhanced axial CT scan combined with 3D angio-

graphic reconstruction can reveal the precise position and spatial relationship between the FB and adjacent structures, thus providing a guide to develop the most correct and safe interventional strategy. 10 Further help in this direction can be provided by the integration of imaging data with intraoperative navigation and cranial nerve monitoring (Intraoperative neural monitoring - IONM)<sup>(11,12,13)</sup>.

In this study we retrospectively examine some emblematic cases among those that occurred in the last few years in our hospital (from January 2008 to December 2017). The aim of this study is to improve the diagnostic classification and management of cases of foreign bodies penetrated in the head and neck region<sup>(14,15)</sup>. An antibiotic treatment is always necessary<sup>(16)</sup>.

## Materials and methods

We retrospectively examined the cases of FB involving Ear Nose and Throat (ENT) district between January 2008 and December 2017. We selected patients of all ages whose management required an intervention under general anaesthesia and with a multidisciplinary approach, which put the patient's survival at risk for the involved anatomical structures. From a total number of 183 patients, 4 patients with multiple district involvement were selected. Of these, in only 2 cases the patients' lives were seriously put in danger and required a multidisciplinary approach.

It was excluded all patients with suspected history of FB in the head and neck district whose management took place in the clinic or in the operating room (OR) with or without general anaesthesia, but without the involvement of other specialist figures or in which the management (even if multidisciplinary) concerned localisations that didn't put in danger the patient's life.

The Aim of the study was to describe the multidisciplinary management of the most complex cases, essential to minimize life risk or major complications and sequelae.

## Results

There were 183 cases of FBs of the head and neck district submitted to extraction in the analysed decade. The affected population's age was between 18 months old and 79 years old; the incidence was slightly higher in the male sex with a male/female ratio of 1.2/1.

The incidence was prevalent among children, with 112 cases against 60 cases in adults (including 11 post-dental care cases).

The most affected site was the upper airway and digestive tract (with 76 cases of which 44 in children and 32 in adults), followed by endonasal FBs with a clear prevalence of incidence in children (40 versus 11). FBs in the outer ear had the lowest incidence, with a total of 41 cases including 28 in children and 13 in adults.

The cases with multiple district involvement were 75% related to accidents at work, while one case remained of dubious interpretation (Table 1).

	Ear	Nose	Oropharynx/Larynx	Multidistrict	Total
Extraction in children	28	40	44		112
Extraction in adults	13	11	32	4 cases of which: - Case 1: wooden FB in the nasolacrimal district - Case 2: wooden FB in the neck/oral cavity/palate/nasal fossa/ethmoid district	51
Total	41	51	76	4	172

**Table 1:** The global casuistry of FBs classified by location, type and management.

In Table 1 we excluded 11 cases of nasal endoscopic sinus surgery due to the removal of iatrogenic FBs as a complication/sequelae of dental surgery. All 4 cases with multiple district involvement were subjected to a contrast-enhanced CT scan and a 3D angiographic reconstruction, which demonstrated a 100% sensitivity in identifying the position and spatial relationship between FBs and adjacent vital blood vessels, providing a fundamental guidance for the therapeutic strategy. Of the 4 cases described, we excluded Case 1 since there was no involvement of vital structures capable of putting at risk the patient's life, and Case 4 due to the fact that the extraction was completed only by the ENT surgeon with the aid of an image intensifier.

The 2 remaining cases described are characterized by the involvement of several districts, the quoad vitam risk and the need for a reasoned multidisciplinary approach in order to minimize potential complications and sequelae. The follow-up evaluation was performed for at least 6 months.

## Results

### Case A

52 yeas-old worker got pierced by a wooden pole (2 x 6 x 110 cm long) fixed to the floor after

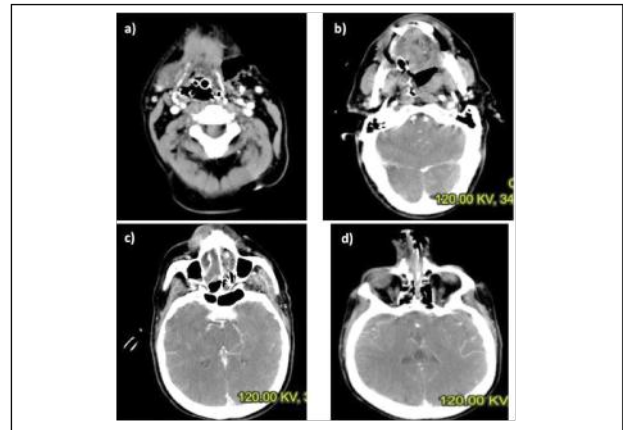
falling down from a scaffolding during work hours. The FB penetrated through the skin of left sub-mandibular space, crossing the oral cavity and reaching the paranasal sinuses, causing an important haemorrhage. He was immediately transported to the nearest hospital for first aid. After being stabilized he was transported with helicopter rescue to our hospital, in which we proceeded administering anti-tetanus prophylaxis, taking blood samples to assess his blood group and ensuring a stable intravenous (IV) access.

The wooden pole, now measuring approximately 2 x 6 x 50 cm, penetrated the left lateral region of the neck below and medially to the left mandibular arch slantwise from bottom to top, from left to right and from the front to the back. The patient was conscious without significant neurological signs and no signs of meningeal irritation, Glasgow Coma Scale (GCS) of 15 (Eye 4, Verbal 5, Motor 6) and body temperature of 37.8°C at admission.

After oro-tracheal intubation and nasogastric tube placement through left nasal fossa, the patient was subjected under narcosis to a contrast-enhanced CT scan of the head and neck district, which documented the penetration of the FB through the left lateral region of the neck on a plane passing below the jaw without causing its fracture (b). The pole then passed through the oropharynx and the palate, crossing the median line, penetrating the right paranasal sinuses and reaching the contralateral posterior ethmoid sinus. The penetration of the ethmoid caused a slight decomposed multi-fragmented fracture of the right papyral lamina with endo-orbital dislocation of some bony lamellae (d). A fracture of the right orbital floor was associated with the presence of multiple gaseous bubbles in the orbital cavity. After the injection of contrast medium, no significant alterations of the intracranial arterial vascular tree nor of the main arterial branches of the facial massif were documented, although a close anatomical relationship was evident between the FB and the left facial and lingual artery, together with the right sphenopalatine artery (Figure 1).

Ophthalmological consultation excluded alterations in ocular motility.

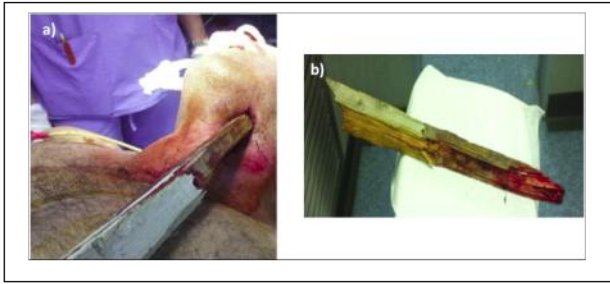
On the basis of clinical and radiological evaluation a team involving anaesthesiologists, otolaryngologists, vascular surgeons, ophthalmologists and maxillofacial surgeons was established; neurosurgeons were not involved. The patient was transported to the OR and, under narcosis, was subjected to



**Fig. 1:** CT scan evidenced penetration of the FB through the left lateral region of the neck (a) below the jaw without causing its fracture (b). The pole then passed through the oropharynx and the palate, crossing the median line, penetrating the right paranasal sinuses and reaching the contralateral posterior ethmoid sinus (c). The penetration of the ethmoid caused a slight decomposed multi-fragmented fracture of the right papyral lamina with endo-orbital dislocation of some bony lamellae (d).

preparation of the left external carotid artery, nasal endoscopy and removal of the FB; fortunately, none of the large blood vessels bled, so it wasn't necessary to proceed with the ligation of the external carotid artery; we proceeded with an endoscopic recognition to ensure the absence of FB's residues at nasal, paranasal and orbital level; we ensured the absence of cerebrospinal fluid (CSF) leakage in the nasal fossae so that the septal fracture could be recomposed; a partial right ethmoidectomy was performed with accurate haemostasis. The fracture of the orbital floor was not repaired due to its limited dimensions and the lack of ocular muscles' involvement. We then proceeded with a trans-oral suture of the palatal and oral floor wounds, closing the neck wound after positioning an aspiration drainage (Figure 2).

The post-operative CT scan confirmed the absence of FB's residues. We administered an effective and sufficient antimicrobial therapy; the patient was held in sub-intensive care for 48 hours and discharged after 5 days; the ophthalmological assessment before discharge showed no diplopia; the nasal endoscopic evaluation showed no aberrant scars with good preservation of good nasal ventilation and absence of sinusopathy; the patient developed paralysis and atrophy of left portion of the tongue due to a lesion of the XII left cranial nerve and a hypoesthesia of the left cheek from an injury to the left lingual nerve.



**Fig 2:** (a) The FB penetrated through the skin of left sub-mandibular space; (b) The wooden pole removed.

### Case B

58 years-old man admitted to our hospital with a 20 cm blade kitchen knife stuck in his neck; the FB penetrated into the right lateral region of the neck at the height of the thyroid cartilage behind its posterior margin, exiting contralateral behind the posterior margin of left SCM muscle.

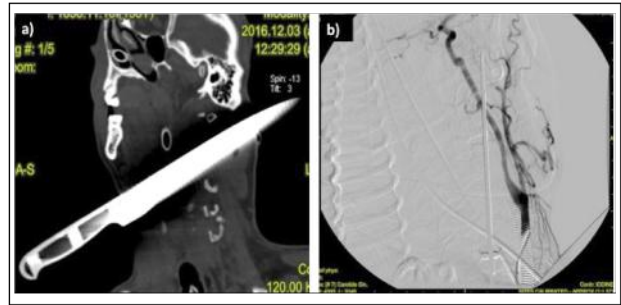
The fiber-optic endoscopic evaluation didn't show any interruptions of the mucosa of the oropharynx/ipopharynx and larynx, nor mucosal haemorrhage. In the ER blood samples were taken to assess his blood group and a stable (IV) access was ensured.

The CT scan done with urgency (not contrast-enhanced) documented presence of a knife with right-hand entrance in the lateral region of the neck, at the level of a plane passing anteriorly through the corpus of C3 and moving laterally beyond the median structures. The FB dubs anteriorly the corpus of C3, exiting on the left lateral region of the neck; it is possible to appreciate an extended tumefaction enveloping the metal FB in correspondence of the right para-pharyngeal space, probably due to a blood collection secondary to an injury of the vascular and nerve structures" (Figure 3a). Due to the metallic artefacts and the relative stability of the patient it was then ensured a left trans-femoral IV access, through which it was possible to execute an angiographic study of the right and left common carotid arteries, the left vertebral artery and the right lingual artery. The study demonstrated no spillage of contrast medium, assuring the anatomical preservation of the studied vascular structures (Figure 3b).

The patient was conscious by the time of the admission, with a GCS of 15 (Eye 4, Verbal 5, Motor 6).

On the basis of clinical and radiological evaluation a team involving anaesthesiologists, otolaryngologists and vascular surgeons was established.

The patient was intubated via the right nasal fossa, transported to the OR and, under narcosis,

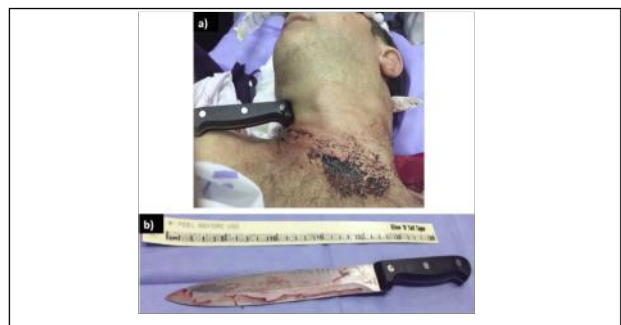

**Fig 3:** (a) CT scan documented presence of a knife with right-hand entrance in the lateral region of the neck, at the level of a plane passing anteriorly through the corpus of C3 and moving laterally beyond the median structures; (b) Angiography study demonstrated anatomical preservation of the vascular structures.

the FB was completely removed along the direction of penetration; during the removal a simultaneous rhinopharyngeal/laryngoscopic surveillance was maintained. No lesions of the pharyngeal/laryngeal mucosa occurred, while a right internal jugular vein (RIJV) injury was repaired with a 6/0 absorbable monofilament suture thread; an aspiration drainage was placed in the right lateral region of the neck and a bilateral suture of the cutaneous planes was performed; no transfusion was needed (figure 4).

The post-operative contrast-enhanced CT scan supplemented with non-selective 3D angiographic study didn't reveal vascular weakening.

We administered antibiotics to prevent infections; no complications were observed after a 6-months follow-up.



**Fig 4:** (a) Blade kitchen knife penetrated in the neck; (b) Blade kitchen knife removed.

### Discussion

To date, there are no standard guidelines for the diagnosis and treatment of FBs in the head and neck district, especially for those more complex cases in which, due to a trauma, there is an involvement of multiple structures and the patient's life is seriously put at risk. The rareness and inhomogene-

ity of the cases (both for the different districts involved and the characteristics of the Fs) make it difficult to implement protocols. There are multiple problems to be faced, with the need to develop, from time to time, complex multidisciplinary therapeutic strategies with variable priorities related to the starting conditions and the complications that may arise during the extraction of the FB; only a proper planning based on clinical and radiological data can allow the prevention and prompt control of any possible complications<sup>(17,18,19)</sup>.

In the reported cases the initial priority was to secure the airways. Subsequently, a careful radiological study was carried out with contrast enhancement completed with a 3D angiographic study in order to obtain a correct assessment of site and dimensions of the FBs together with the anatomical relations between the FBs and the neighbouring vital structures (especially big blood vessel); from the evaluation of the imaging we proceeded to programme the most appropriate surgical strategy that could involve multiple specialties (otolaryngologists, neurosurgeons, interventional radiologists, vascular surgeons, ophthalmologists, maxillofacial surgeons plus radiologists and anaesthesiologists)<sup>(20-23)</sup>; the main goal of the team work is to be ready for the management of any complications that can put the patient's life at risk. In particular cases the use of navigation systems, brightness intensifiers and cranial nerve monitoring systems can be taken into consideration<sup>(24-31)</sup>. Postoperative CT scans are almost always essential, mandatory in case of friable foreign bodies to check for remaining residues<sup>(32-40)</sup>.

## References

- 1) Tan SS, Yeo MS, Lee G, Ho M, Ang ML, Lee W, Cheong EC. Penetrating foreign body in the masticator space with injury to the internal maxillary artery: a surgical challenge. *Ann R Coll Surg Engl*. 2016 Nov; 98(8): e194-e196. Epub 2016 Aug 23
- 2) Santoro R, Mannella VK, Freni F, Galletti F. Penetrating foreign body in the nasal floor through nasolacrimal duct. *BMJ Case Rep*. 2014 Jun 12; 2014
- 3) Sireci F, Nicolotti M, Battaglia P, Sorrentino R, Castelnuovo P, Canevari FR. Canine fossa puncture in endoscopic sinus surgery: report of two cases. *Braz J Otorhinolaryngol*. 2017 Sep - Oct; 83(5): 594-599. doi: 10.1016/j.bjorl.2017.03.001.
- 4) Sireci F, Martines F, De Bernardi F, Poma S, Dispenza F, Galletti B, Galletti F, Canevari FR. Canine Fossa Puncture for the Management of Maxillary Sinusitis In: Heather Gilbert eds. *Handbook of Surgical Procedures*. Chapter 9; Nova publisher
- 5) Galletti B, Santoro R, Mannella VK, Caminiti F, Bonanno L, De Salvo S, Cammaroto G, Galletti F. Olfactory event-related potentials: a new approach for the evaluation of olfaction in nasopharyngeal carcinoma patients treated with chemo-radiotherapy. *J Laryngol Otol*. 2016 May; 130(5): 453-61.
- 6) Ottaviano G, Maculan P, Borghetto G, Favero V, Galletti B, Savietto E, Scarpa B, Martini A, Stellini E, De Filippis C, Favero L. Nasal function before and after rapid maxillary expansion in children: A randomized, prospective, controlled study. *Int J Pediatr Otorhinolaryngol*. 2018 Dec; 115: 133-138.
- 7) Galletti C, Cammaroto G, Galletti F, Camps-Font O, Gay-Escoda C, Bara-Casaus JJ. Dental implants after the use of bichat's buccal fat pad for the sealing of oro-antral communications. A case report and literature review. *J Clin Exp Dent*. 2016 Dec 1; 8(5): e645-e649.
- 8) Cammaroto G, Montevecchi F, D'Agostino G, Zeccardo E, Bellini C, Galletti B, Shams M, Negm H, Vicini C. Tongue reduction for OSAHS: TORSs vs coblations, technologies vs techniques, apples vs oranges. *Eur Arch Otorhinolaryngol*. 2017 Feb; 274(2): 637-645. doi: 10.1007/s00405-016-4112-4.
- 9) Choi KJ, Ryan MA, Cheng T, Powers D. Penetrating Craniomaxillofacial Injury Caused by a Pneumatic Nail Gun. *Craniomaxillofac Trauma Reconstr*. 2017 Jun; 10(2): 159-161. Epub 2016 Jun 27.
- 10) Kim SW, Youn SK, Kim JT, Cho SH, Kim YH, Hwang KT. Management of an unusual craniofacial impalement injury by a metallic foreign body. *J Craniofac Surg*. 2012 Mar; 23(2): e140-6.
- 11) Fleiter TR, Mervis S. The role of 3D-CTA in the assessment of peripheral vascular lesions in trauma patients. *Eur J Radiol*. 2007 Oct; 64(1): 92-102. Epub 2007 Sep 14.
- 12) Medina MV, Pollak N. Removal of an intra-parotid foreign body without parotidectomy and dissection of the facial nerve. *Laryngoscope*. 2010;120 Suppl 4: S132
- 13) Sun H, Zanghì GN, Freni F, Dionigi G. Continuous and intermitted nerve monitoring in thyroid surgery: two complementary devices. *Gland Surg*. 2018 Aug; 7(Suppl 1): S80-S81
- 14) Cristofari E, Cuda D, Martini A, Forli F, Zanetti D, Di Lisi D, Marsella P, Marchioni D, Vincenti V, Aimoni C, Paludetti G, Barezzi MG, Leone CA, Quaranta N, Bianchedi M, Presutti L, Della Volpe A, Redaelli de Zinis LO, Cantore I, Frau GN, Orzan E, Galletti F, Vitale S, Raso F, Negri M, Trabalzini F, Livi W, Piccioni LO, Ricci G, Malerba P. A Multicenter Clinical Evaluation of Data Logging in Cochlear Implant Recipients Using Automated Scene Classification Technologies. *Audiol Neurootol*. 2017; 22(4-5): 226-235.
- 15) Ciodaro F, Mannella VK, Cammaroto G, Bonanno L, Galletti F, Galletti B. Oral gabapentin and intradermal injection of lidocaine: is there any role in the treatment of moderate/severe tinnitus? *Eur Arch Otorhinolaryngol*. 2015 Oct;272(10):2825-30.
- 16) Galletti B, Mannella VK, Santoro R, Rodriguez-Morales AJ, Freni F, Galletti C, Galletti F, Cascio A. Ear, nose and throat (ENT) involvement in zoonotic diseases: a systematic review. *J Infect Dev Ctries*. 2014

- Jan 15;8(1):17-23. doi: 10.3855/jidc.4206.
- 17) Salvago P, Rizzo S, Bianco A, Martines F. Sudden sensorineural hearing loss: is there a relationship between routine haematological parameters and audiogram shapes? *Int J Audiol.* 2017 Mar;56(3):148-153.
  - 18) Galletti F, Cammaroto G, Galletti B, Quartuccio N, Di Mauro F, Baldari S. Technetium-99m (<sup>99m</sup>Tc)-labelled sulesomab in the management of malignant external otitis: is there any role? *Eur Arch Otorhinolaryngol.* 2015 Jun; 272(6): 1377-82.
  - 19) Martines F, Ballacchino A, Sireci F, Mucia M, La Mattina E, Rizzo S, Salvago P. Audiologic profile of OSAS and simple snoring patients: the effect of chronic nocturnal intermittent hypoxia on auditory function. *Eur Arch Otorhinolaryngol.* 2016 Jun; 273(6): 1419-24.
  - 20) Motta G, Motta S, Cassano P, Conticello S, Ferretti M, Galletti B, Garozzo A, Larotonda G, Mansi N, Mevio E, Motta G, Quaremba G, Serra A, Tarantino V, Tavormina P, Vicini C, Vigili MG, Testa D. Effects of guidelines on adeno-tonsillar surgery on the clinical behaviour of otorhinolaryngologists in Italy. *BMC Ear Nose Throat Disord.* 2013 Jan 7;13:1.
  - 21) Galletti B, Freni F, Cammaroto G, Catalano N, Gangemi G, Galletti F. Vocal outcome after CO2 laser cordectomy performed on patients affected by early glottic carcinoma. *J Voice.* 2012 Nov;26(6):801-5.
  - 22) Marseglia L, D'Angelo G, Impellizzeri P, Salvo V, Catalano N, Bruno R, Galletti C, Galletti B, Galletti F, Gitto E. Neonatal stridor and laryngeal cyst: Which comes first? *Pediatr Int.* 2017 Jan;59(1):115-117.
  - 23) Canevari FR, Martines F, Sorrentino R, Nicolotti M, Sireci F. Pseudoaneurysm of superior thyroid artery following a transesophageal echocardiography: a case presentation. *Euromediterranean Biomedical Journal* 2017, 12(03): 010-012
  - 24) Galletti B, Gazia F, Freni F, Sireci F, Galletti F. Endoscopic sinus surgery with and without computer assisted navigation: A retrospective study. *Auris Nasus Larynx.* 2018; 10.1016/j.anl.2018.11.004
  - 25) Galletti B, Bruno R, Catalano N, Cammaroto G, Freni F. Follicular carcinoma on a radio-treated ectopic lingual thyroid. *Chirurgia (Turin).* 2016 June; 29(3): 88-91
  - 26) Naro A, Leo A, Bruno R, Cannavò A, Buda A, Manuli A, Bramanti A, Bramanti P, Calabrò RS. Reducing the rate of misdiagnosis in patients with chronic disorders of consciousness: Is there a place for audiovisual stimulation? *Restor Neurol Neurosci.* 2017; 35(5): 511-526.
  - 27) Naro A, Bruno R, Leo A, Russo M, Salviera C, Bramanti A, Bramanti P, Calabrò RS. Twist and turn into chronic disorders of consciousness: Potential role of the auditory stapedial reflex. *Restor Neurol Neurosci.* 2017; 35(1): 77-85.
  - 28) Leo A, Naro A, Cannavò A, Pisani LR, Bruno R, Salviera C, Bramanti P, Calabrò RS. Could autonomic system assessment be helpful in disorders of consciousness diagnosis? A neurophysiological study. *Exp Brain Res.* 2016 Aug; 234(8): 2189-99
  - 29) Ciodaro F, Mannella VK, Nicita RA, Cammaroto G, Bruno R, Galletti B, Freni F, Galletti F. Therapeutic efficacy of the Galletti-Contrino manoeuvre for benign paroxysmal positional vertigo of vertical semicircular canals in overweight subjects. *Eur Arch Otorhinolaryngol.* 2018 Oct; 275(10): 2449-2455.
  - 30) Naro A, Leo A, Cannavò A, Buda A, Bruno R, Salviera C, Bramanti P, Calabrò RS. Audiomotor Integration in Minimally Conscious State: Proof of Concept! *Neural Plast.* 2015; 2015: 391349. doi: 10.1155/2015/391349.
  - 31) Mento C, Galletti F, Freni F, Longo P, Testini G, Rizzo A, Settineri S. The role of temperament in traumatic hearing loss: a single case study of a cochlear-implanted patient. *Int J Adolesc Med Health.* 2016 Feb; 28(1): 107-13.
  - 32) De Salvo S, Bonanno L, Giorgianni R, Muscarà N, Freni F, Caminiti F, Milardi D, Bramanti P, Marino S. Functional MRI and laser-evoked potentials evaluation in Charcot-Marie-Tooth syndrome. *Neurol Sci.* 2018 Jul; 39(7): 1185-1189.
  - 33) Freni F, Galletti B, Galletti F, Dionigi G. Improved outcomes for papillary thyroid microcarcinoma care: active surveillance and case volume. *Ther Adv Endocrinol Metab.* 2018 Jul; 9(7): 185-186.
  - 34) Catalano N, Cammaroto G, Galletti B, Freni F, Nicita RA, Azielli C, Galletti F. The role of cVEMPs and vHIT in the evaluation of otosclerosis and its eventual vestibular impairment: preliminary findings. *B-ENT.* 2017; 13(1 Suppl 27): 31-36
  - 35) Freni F, Mannella VK, Cammaroto G, Azielli C, Cappuccio C, Galletti F. Classic and reversal steps stapedotomy performed with CO2 laser: a comparative analysis. *Eur Arch Otorhinolaryngol.* 2014 May; 271(5): 981-6.
  - 36) Galletti B, Mannella VK, Santoro R, Cammaroto G, Freni F, Galletti F, Cascio A. Malignant external otitis. A case series from an Italian Tertiary-Care Hospital. *2014 Acta Medica Mediterranea.* 2014; 30(6): 1317-1323
  - 37) Bruno R, Aversa T, Catena M, Valenzise M, Lombardo F, De Luca F, Wasniewska M. Even in the era of congenital hypothyroidism screening mild and subclinical sensorineural hearing loss remains a relatively common complication of severe congenital hypothyroidism. *Hear Res.* 2015 Sep; 327: 43-7.
  - 38) Amorini M, Romeo P, Bruno R, Galletti F, Di Bella C, Longo P, Briuglia S, Salpietro C, Rigoli L. Prevalence of Deafness-Associated Connexin-26 (GJB2) and Connexin-30 (GJB6) Pathogenic Alleles in a Large Patient Cohort from Eastern Sicily. *Ann Hum Genet.* 2015 Sep; 79(5): 341-349.
  - 39) Miroddi M, Bruno R, Galletti F, Calapai F, Navarra M, Gangemi S, Calapai G. Clinical pharmacology of melatonin in the treatment of tinnitus: a review. *Eur J Clin Pharmacol.* 2015 Mar; 71(3): 263-70.
  - 40) Naro A, Leo A, Cannavò A, Buda A, Bruno R, Salviera C, Bramanti P, Calabrò RS. Audiomotor Integration in Minimally Conscious State: Proof of Concept! *Neural Plast.* 2015; 2015: 391349. doi: 10.1155/2015/391349.

---

*Corresponding author*

FEDERICO SIRECI (MD)

Department of Adult and Development Age Human Pathology "Gaetano Barresi"

unit of Otorhinolaryngology, University of Messina

Via Consolare Valeria 1

98125, Messina, ME

E-mail: federicosireci@hotmail.it

(Italy)